RETURN TO 1998 ROD AR INDEX

17.7.52

Superfund Records Center
SITE: New Bedford
BREAK: 17.07
OTHER:
SDMS DocID 000200921

Environmental Health Perspectives
Vol. 60, pp. 97-105, 1985

Polychlorinated Biphenyl Induction of Hepatocellular Carcinoma in the Sprague-Dawley Rat

by D. H. Norback* and Robert H. Weltman*†

Male and female Sprague-Dawley rats (70 males and 70 females in the initial group) were fed a diet containing a polychlorinated biphenyl mixture (Aroclor 1260, 100 ppm for 16 months and 50 ppm for an additional 8 months) for 2 years followed by a control diet for 5 months. A control group initially consisted of 63 males and 63 females. Sequential morphologic changes were evaluated throughout the study. In the PCB-exposed group the following hepatocellular lesions developed in sequence: centrolobular cell hypertrophy at 1 month, foci of cell alteration at 3 months, areas at 6 months, neoplastic nodules at 12 months, trabecular carcinoma at 15 months, and adenocarcinoma at 24 months. In addition, simple and cystic cholangioma at 18 and 23 months, respectively, and adenofibrosis at 22 months were present. With the exception of hepatocyte hypertrophy and adenofibrosis, all lesions contained cells that were positive for gamma glutamyl transpeptidase activity. In the PCB-exposed group that was examined after 18 months, hepatocellular neoplasms were present in 95% of the 47 females and in 15% of the 46 males. Distant organ metastases did not occur and the mortality rate was not increased in the PCB exposed group. In 81 control rats examined after the 18th month, only 1 hepatocellular neoplasm (a neoplastic nodule) occurred. PCB-exposed and control rats developed simple cholangioma, cystic cholangioma and adenofibrosis; the incidence of each was greater in the PCB group. Thus, within the Sprague-Dawley rat group exposed to a diet with relatively high concentrations of Aroclor 1260 for 2 years a hepatocarcinogenic effect manifested by formation of slowly growing hepatocellular carcinomas was produced. The incidence of hepatocellular neoplasms in females was strikingly greater than in males.

Introduction

Polychlorinated biphenyl (PCB) mixtures have produced a variety of oncogenic effects in the rat liver. Adenofibrosis developed in male and female Sherman rats which received a diet containing 500 μg Aroclor 1254/g for 30 weeks (*1*), in female Sherman rats which received a diet containing 100 μg Aroclor 1260/g for 21 months (*2*), and in male Wistar rats which received a diet containing 1 mg Kanechlor 500, 400 or 300/g for 40 to 52 weeks (*3*). Foci and areas of hepatocyte alteration and neoplastic nodules developed in female Sherman rats which received 100 μg Aroclor 1260/g diet for 21 months (*2*). Neoplastic nodules also developed in female, but not male. Donryo rats which received a diet containing Kanechlor 400 ranging in concentration from 33.5 to 616 μg/g for 400 days (*4*) and in male Wistar rats which received a diet containing 100 μg Kanechlor 500, 400 or 300/g for 40 to 52 weeks (*3*). Hepatocellular carcinoma developed in female Sherman rats which received 100 μg Aroclor 1260/g diet for 21 months (*2*). Liver lesions designated as hepatomas by the investigator occurred in albino rats which received 100 μg of Aroclor 1242, 1245 or 1260/g diet for 24 months (*5*).

We investigated the hepatocarcinogenic potential of the highly chlorinated PCB mixture Aroclor 1260 in another strain of rat, the Sprague-Dawley, which has a low incidence of spontaneous hepatocellular neoplasms (*6*), Enzyme histochemistry and other morphologic studies further characterized the lesions. The study, which spanned the natural life of the animal, allowed us to further evaluate the potential of the hepatocellular carcinoma to metastasize to distant organs and the effect of PCBs on longevity of the animal. Morphologic studies of the liver throughout the course of the experiment permitted evaluation of the sequential development of the liver lesions. The incidence of tumors occurring in male and female rats was determined.

Materials and Methods

Weanling Sprague-Dawley rats, initially weighing 100 gm, were divided into two groups. The PCB-treated group, initially containing 70 males and 70 females, re-

*University of Wisconsin, Clinical Laboratories, Department of Pathology and Laboratory Medicine, Madison, WI 53792.
†Present address: Hazleton Laboratories America Inc., P.O. Box 7545, Madison, WI 53707.

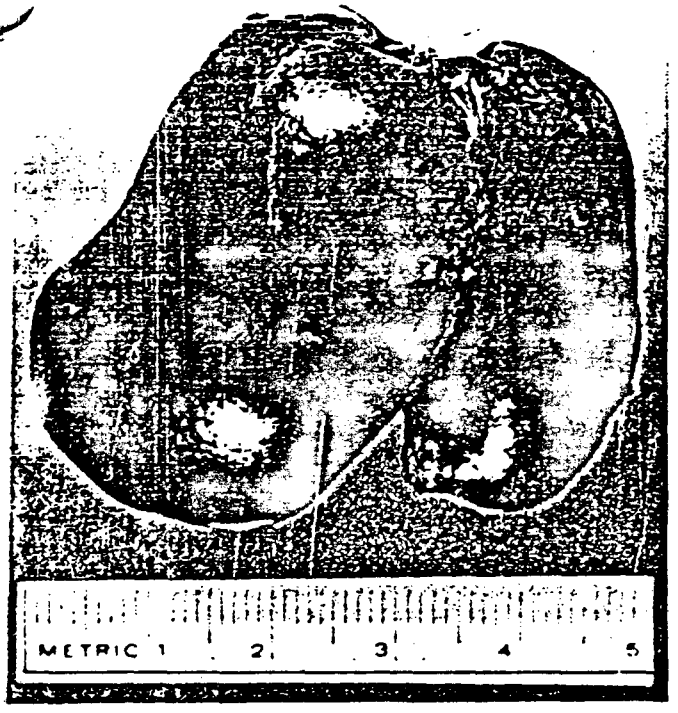

FIGURE 1. PCB-exposed rat liver; at 23 months. The liver surface is dotted with nonelevated tan foci, 0.5 to 1 mm in diameter. A neoplastic nodule is present at the tip of one lobe.

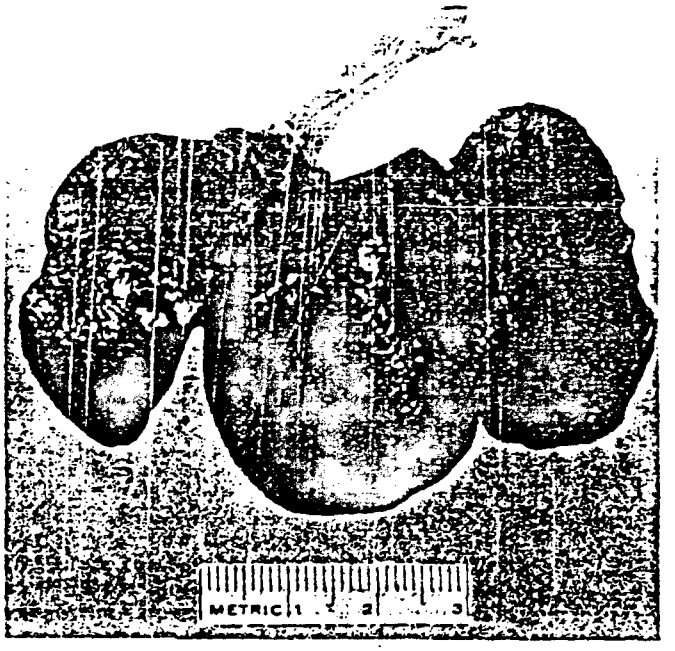

FIGURE 2. PCB-exposed rat liver; at 27 months. One lobe (cut surface) is replaced by hepatocellular carcinoma with necrotic center. A neoplastic nodule protrudes from another lobe. Small tan foci are numerous.

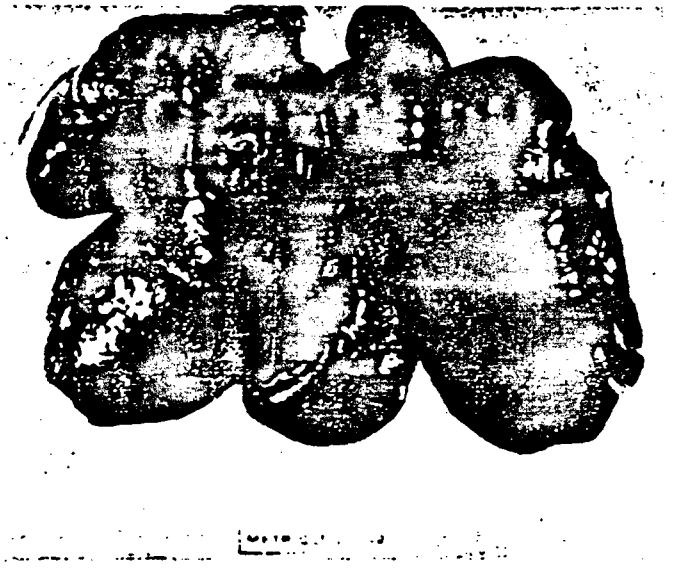

FIGURE 3. PCB-exposed rat liver; the liver lobe (at left) is replaced by adenocarcinoma which appeared as a tan tumor with cysts at the 29th month. Adenofibrosis is observed as a firm white lesion with central depression.

eived a basal diet (Purina Rat Chow, St. Louis, MO) with added Aroclor 1260 (Monsanto Chemical Co., St. Louis, MO) at a concentration of 100 μg/g diet for 16 months and 50 μg/g diet for an additional 8 months. The diet was prepared by mixing Aroclor 1260 with corn oil, adding the mixture to ground chow, and pelleting the final mixture. The control group, initially containing 63 males and 63 females, received the basal diet with added corn oil for 18 months and the basal diet alone for an additional 5 months. All surviving rats received the basal diet from the 25th month to the 29th month. Both groups received water *ad libitum*. After a 24-hr fast, the medial and left lobes of the liver of ten etherized rats (two male controls, two female controls, three male PCB-treated, and three female PCB-treated rats for each time period) were removed at 1, 3, 6, 9, 12, 15 and 18 months. Partial hepatectomy was performed once per animal in these groups. At 24 months a similar group and at 29 months all remaining animals were sacrificed. Throughout the study moribund rats were sacrificed. At death all rats were necropsied. Liver weights and body weights were recorded. Representative slices from all liver tissue obtained at surgery and at necropsy, and slices from other selected organs obtained at necropsy, were prepared for microscopy. Tissue slices were placed in a formaldehyde fixative, dehydrated in ethanol, embedded in paraffin, sectioned at 5 μm, and stained with hematoxylin and eosin (H + E) or periodic acid–Schiff (PAS) stain. Liver tissue was also diced into 1 mm cubes, fixed in 2.5% glutaraldehyde buffered with 0.1 M sodium phosphate (pH 7.4–7.5) for 4 to 24 hr, rinsed with buffer, post-fixed in 1% osmium tetroxide buffered with 0.1 M veronal acetate (pH 7.4) for 30 min, dehydrated in ethanol, infiltrated with propylene oxide and then Epon-Araldite, sectioned at 1 to 2 μm and stained with Toluidine Blue (TB). Between 9 and 29 months, liver slices from at least two animals of each group at each examination time point were frozen on dry ice and processed for γ-glutamyl transpeptidase (GGT) activity according to the procedure of Rutenburg et al. (7).

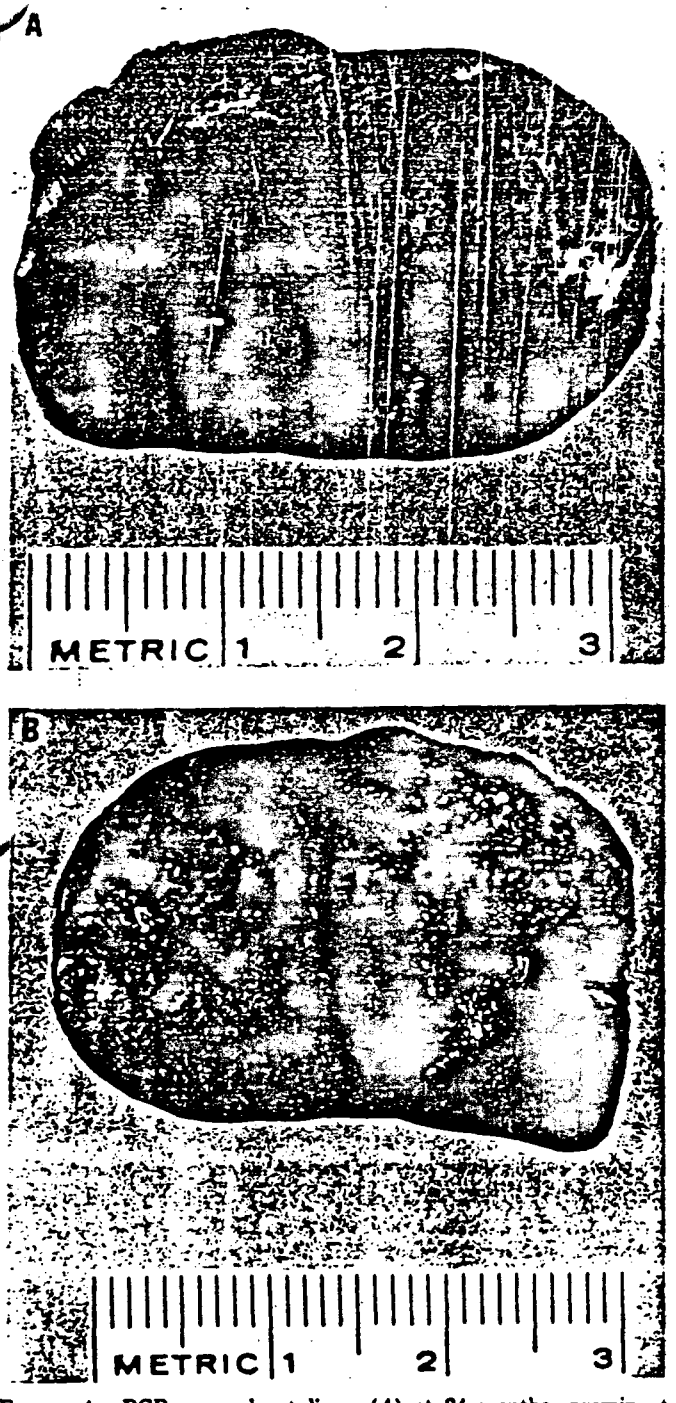

FIGURE 4. PCB-exposed rat liver; (*A*) at 24 months, prominent vasculature and cystic spaces of this hepatocellular carcinoma are evident through the hepatic capsule; (*B*) the cut surface shows irregular borders and extensive replacement of the lobe.



FIGURE 5. Control rat liver, a central vein, portal triads, thin plates of uniform hepatocytes, and endothelial-lined sinusoids were structures of the normal liver as demonstrated from a rat fed the control diet for 9 months. H & E; ×160.



FIGURE 6. Hypertrophic hepatocytes developed in the central lobular region of the liver obtained at 1 month. H & E; ×160.

Results

Macroscopic

Chronic dietary administration of Aroclor 1260 caused early and progressive liver alterations in the Sprague-Dawley rats. Hepatomegaly was apparent during surgery at the first month, and after 18 months the livers of female rats averaged 12% of the body weight, while the control averaged 4%. Small (1 mm) tan areas (Fig. 1) were readily apparent on the capsular surface. Neoplastic nodules (Figs. 1 and 2) near the capsular surface protruded and compressed the surrounding parenchyma. Hepatocellular carcinoma (Figs. 2–4) often replaced the major portion of the lobe and elevated the liver surface. The size ranged from 0.5 to 6.0 cm. Surface vessels were often apparent through the capsule. The ill-defined borders compressed the adjacent parenchyma. Portions of the tumor were hemorrhagic or necrotic. Some tumors contained cystic areas with clear fluid (Fig. 3). Adenofibrosis (Fig. 3) appeared as a firm white area with central depression. In some livers, all lesions were present.

Microscopic

The hepatocellular lesions were classified according to recommendations of Stewart et al. (*8*). For the cholangiocellular lesions, the nomenclature of Schauer and



FIGURE 7. Foci of altered cells developed in the central and middle lobular regions in this liver obtained at 9 months. The cells merged with adjacent hepatic plates. Cells of the focus were usually eosinophilic and larger than normal. H & E; ×150.

FIGURE 8. This enzyme altered focus was present at 9 months. GGT; ×160.

FIGURE 9. This neoplastic nodule in a liver obtained at 15 months lacked lobular architecture and compressed the adjacent nontumor parenchyma. H & E; ×40.



FIGURE 10. Cells, nuclei, and nucleoli in the neoplastic nodule described for Fig. 9 were larger than their counterparts of the adjacent parenchyma. In this preparation, the nucleus is light with a very dark nucleolus. The granularity of the cytoplasm is mainly due to mitochondria. TB; ×400.



FIGURE 11. In a trabecular carcinoma from a liver obtained at 24 months, wide plates of cells were separated by sinusoids. The large cells contained large, abnormal nuclei. H & E; ×160.

Kunze (*9*) is applied. The normal architecture of the liver is shown in Figure 5. In the PCB-exposed group, the following hepatocellular lesions were observed in sequence (Table 1): centrolobular cell hypertrophy (Fig. 6) at 1 month, foci (Figs. 7 and 8) at 3 months and then areas of cell alteration at 6 months, neoplastic nodules (Figs. 9 and 10) at 12 months, trabecular carcinoma (Figs. 11 and 12) at 15 months, and adenocarcinoma (Fig. 13) at 24 months. In addition, simple (Fig. 14) and cystic (Fig. 15) cholangioma at 18 and 23 months, respectively, and adenofibrosis (Fig. 16) at 22 months were present.

There was no evidence of metastasis to the lung by gross or microscopic examination.

Control livers and livers containing all lesions were evaluated for GGT activity. Throughout the study, GGT positive areas of hepatocytes were absent in control

Table 1. Development of preneoplastic and neoplastic hepatocellular lesions in male and female rats during chronic Aroclor 1260 exposure.[a]

	No. of livers with lesions of each three sampled															
	1 mo.		3 mo.		6 mo.		9 mo.		12 mo.		15 mo.		18 mo.		24 mo.	
Lesion	M	F	M	F	M	F	M	F	M	F	M	F	M	F	M	F
Focus	0[2]	0	2	2	3	3	3	3	3	3	3	3	3	3	3	3
Area	0	0	0	0	1	0	2	1	0	3	1	3	0	3	3	2
Neoplastic nodule	0	0	0	0	0	0	0	0	0	1	0	3	0	3	1	3
Trabecular carcinoma	0	0	0	0	0	0	0	0	0	0	0	1	0	2	0	2
Adenocarcinoma	0	0	0	0	0	0	0	0	0	0	0	0	0	0	0	2

[a]These lesions were not present in sequentially sampled control liver.

Table 2. Incidence of Aroclor 1260-exposed and control animals containing hepatocellular neoplasms.

	Incidence in Aroclor 1260 animals, %[a]			Incidence in control animals, %[a]		
	Total (N = 93)	Male (N = 46)[b]	Female (N = 47)[c]	Total (N = 81)	Male (N = 32)[d]	Female (N = 49)[e]
Trabecular carcinoma[f]	23(21)	4(2)	40(19)	0	0	0
Adenocarcinoma[f,g]	26(24)	0	51(24)	0	0	0
Neoplastic nodule only	8(7)	11(5)	4(2)	1(1)	0	2(1)
Negative	44(41)	85(39)	4(2)	99(80)	100	98(48)

[a]Figures in parentheses denote number of animals which survived 18 mo. or longer.
[b]Includes eight animals that had received a partial hepatectomy during the first 18 mo.
[c]Includes seven animals that had received a partial hepatectomy during the first 18 mo.
[d]Includes eight animals that had received a partial hepatectomy during the first 18 mo.
[e]Includes ten animals that had received a partial hepatectomy during the first 18 mo.
[f]Animals containing neoplastic nodules plus carcinoma were only included in the carcinoma category.
[g]Animals with trabecular carcinoma and adenocarcinoma were only placed in adenocarcinoma category.



FIGURE 12. Some sections of trabecular carcinoma obtained at 24 months contained numerous mitoses. H & E; ×200.

rats. Hypertrophic cells of the center of the lobule were uniformly negative. Some foci of cell alteration were strongly positive (Fig. 8). Neoplastic nodules and hepatocellular carcinomas (13G) contained positive cells admixed with negative cells. The cells lining the luminal structure of adenocarcinoma were more strongly positive than the cells forming trabecular structures (13G). In the one adenofibrosis evaluated for GGT activity, the ductal cells were GGT negative while entrapped hepatocytes, bile duct cells, and cystic cholangioana cells were positive (Fig. 17).

All adenocarcinomas had elements of trabecular patterns of growth, and all trabecular carcinomas had cell arrangements that resembled a glandular, ductal, or cystic pattern. The apparent lumens of adenocarcinoma probably result from individual cell necrosis within a trabeculum, formation of large canalicularlike structures, cross sections of sinusoids, or glandlike formations formed from cells that differentiate toward the cuboidal or columnar morphology. Close association of hepatocytelike cells and ductal-type cells lining the cystic space, as well as the presence of cells with intermediate morphology (Fig. 13F), suggests a common origin of the cells in adenocarcinoma.

The percentage of animals with hepatocellular neoplasms occurring in animals that survived for 18 months or longer is presented in Table 2. Hepatocellular neoplasms were uncommon in control rats; only one (4 mm diameter) hepatocellular neoplasm occurred in 81 control animals examined. Hepatocellular neoplasms developed in over 55% of the 93 livers (7 males and 45 females) examined after the 18th month. Females had the highest incidence of heptocellular neoplasms; more than 95% developed tumors. Few males developed tumors; neoplastic nodules were present in 11% and hepatocellular carcinoma in 4%.

Treated and control rats developed cholangiocellular

Table 3. Incidence of Aroclor 1260-exposed and control animals containing cholangiocellular lesions.

	Incidence in Aroclor 1260 animals, % [a,b]			Incidence in control animals, % [c]		
	Total (N = 93)	Male (N = 46)[d]	Female (N = 47)[e]	Total (N = 81)	Male (N = 32)[d]	Female (N = 49)[e]
Cholangioma (simple)	38(35)	30(14)	45(21)	5(4)	6(2)	4(2)
Cholangioma (cystic)[f]	8(7)	4(2)	10(5)	1(1)	0	2(1)
Adenofibrosis[g]	9(8)	2(1)	15(7)	4(3)	6(2)	2(1)
Negative	46(43)	63(29)	30(14)	90(73)	88(28)	92(45)

[a]Figures in parentheses denote number of animals which survived 18 mo. or longer.
[b]Includes eight animals that had received a partial hepatectomy during the first 18 mo.
[c]Includes seven animals that had received a partial hepatectomy during the first 18 mo.
[d]Includes eight animals that had received a partial hepatectomy during the first 18 mo.
[e]Includes ten animals that had received a partial hepatectomy during the first 18 mo.
[f]Animals contain simple cholangioma (but not adenofibrosis).
[g]Animals also containing cholangioma were placed in this group.

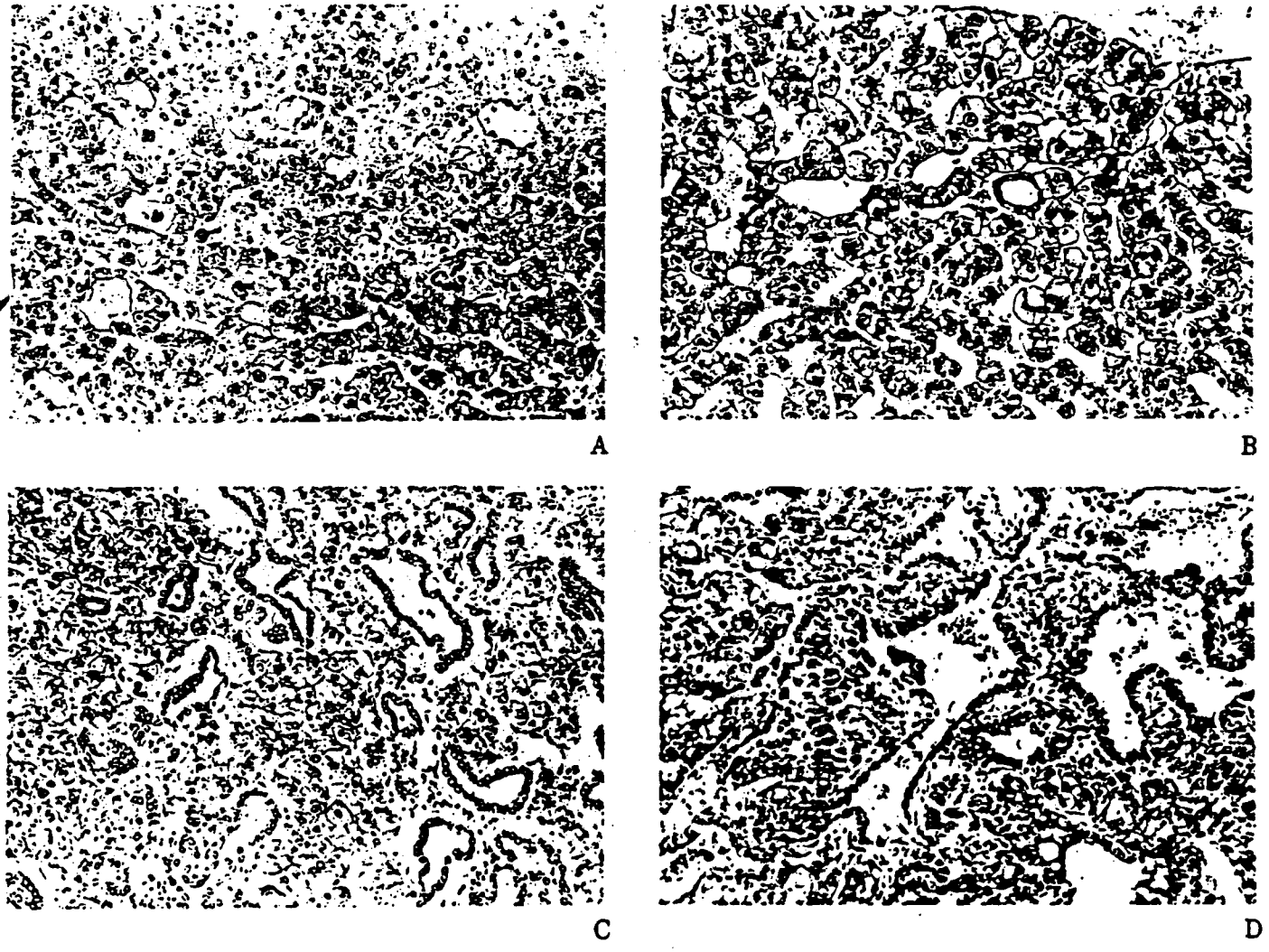

FIGURE 13. All tumors with adenocarcinoma pattern contained trabecular regions. The cells forming gland-, duct-, or cystlike structures appeared to be hepatocellular with unusual features and the luminal structures likely arose from several processes. (A) In this liver obtained at 24 months, some cystic spaces appeared to result from degeneration of individual cells within trabeculae: H & E, ×160. (B) In this liver obtained at 29 months, the glandular spaces represent exaggerated canaliculi formed by three to five hepatocytes. Occasionally, a cross section of a sinusoid may appear as a glandular lumen; however, the presence of endothelial cells should exclude this interpretation: H & E, ×180. (C) In this liver obtained at 29 months, cuboidal cells formed duct-or cyst-like structures among hepatocyte-type cells; H & E, ×160. (D) In this liver obtained at 29 months, columnar cells also lined duct-like structures and covered papillary projections: H & E, ×160.

E



F

G

FIGURE 13 (con't). (E) In this liver obtained at 29 months, intracellular mucus was not demonstrated with special stains; PAS, ×180. (F) Cells lining ductlike structures with hepatocellular-type morphology were continuous with the cuboidal cells; TB, ×300. (G) In a carcinoma with trabecular and adeno- patterns, the lining cells are strongly GGT-positive, and the trabeculae show a variegated pattern; GGT, ×140.

lesions. The simple cholangioma, cystic cholangioma, and cholangiofibrosis of Schauer and Kunze (*9*) are referred to as bile duct hyperplasia, cyst, and adenofibrosis, respectively, by Stewart et al. (*8*). Although the cholangiocellular tumors occurred in the control rats, the incidence of each was greater in the PCB-treated group (Table 3).

Discussion

Hepatocarcinogenic activity of PCBs was demonstrated in the Spague-Dawley rat after long term exposure to relatively high dietary concentrations of Aroclor 1260. Large hepatocellular carcinomas, measuring up to 6 cm in diameter, nearly replaced the liver lobes. Histologic features of carcinoma included wide trabeculae formed from large hepatocytelike cells containing large abnormal nuclei with clumped peripheral chromatin and huge nucleoli. Some microscopic fields contained numerous mitotic figures. Central necrosis and hemorrhage were sometimes present. The tumors were not encapsulated and extended into the adjacent nontumorous parenchyma.

Although the tumors met the morphologic criteria for malignancy, their biologic behavior was relatively unaggressive. The neoplasms did not metastasize to distant organs nor invade blood vessels. Mortality of the animals was not increased. The lack of greater morbidity or mortality is likely due to slow progression of the neoplastic process and late appearance and slow growth of the hepatocellular carcinoma.

PCBs have been established as very effective promoters in carcinogenesis. Kanechlor 400 (400 μg/g diet given for 6 months) after 3′-methyl-4-dimethylaminoazobenzene increased the incidence of hepatocarcinoma over that for the initiator alone in female Donryo rats in the 800-day study (*10*). Kanechlor 500 (0.01 mL given twice weekly by gastric intubation for 12 weeks) resulted in liver tumors at 40 and 52 weeks in male Wistar rats (*11*). Kanechlor 500 (500 or 1000 μg/g diet) caused development of neoplastic nodules in male F344 rats when given for 8 weeks after a nontumorigenic dose of *N*-2-fluorenylacetamide (*12*). Aroclor 1254 (100 μg/g diet for 18 weeks) increased the incidence of hepatocellular carcinoma when given to male Sprague-Dawley rats after diethylnitrosamine (*13*). Aroclor 1254 (500 mg/kg body weight given by intraperitoneal injection) reduced the time required for the appearance of enzyme altered foci in partially hepatectomized male Sprague- Dawley rats (*14*).

It remains to be established whether PCBs also have an initiating effect or whether the neoplasms result from promotion of a background incidence of initiated cells. In hepatocarcinogenesis, it is difficult to distinguish a



FIGURE 14. A simple cholangioma, a proliferation of bile ducts, occurred in a periportal region at 18 months. H & E; ×160.

FIGURE 15. A cystic cholangioma, which does not compress surrounding parenchyma, was present at the 29th month. H & E; ×160.

FIGURE 16. Adenofibrosis obtained at 24 months consisted of gland-like structures formed from columnar epithelium surrounded by abundant stroma. Some cells contained mucin. PAS; ×160.

FIGURE 17. Glandular formations of adenofibrosis are negative for GGT activity, while cystic cholangioma and a focus of hepatocytes were positive. GGT; ×30.

weak initiator from a strong promoter (*15*). A possible mechanism of initiation by PCBs is the formation of an arene oxide of a PCB analog, which is an electrophilic intermediate metabolite capable of forming an adduct with DNA. The identification of a *trans*- dihydrodiol in the rat (*16*) supports the supposition that the PCBs are metabolized via arene oxides. Evidence against the ability of PCBs to act as an initiator resulted from mutagenic studies. While most initiators tested with the Salmonella/microsome test are detected as mutagens (*17*), a PCB mixture (Aroclor 1254) was not mutagenic in the Salmonella assay in the absence or presence of uninduced or PCB-induced rat liver homogenate (*18*).

Hepatocellular lesions developed in more than 95% of the Aroclor 1260 fed female rats, whereas male rats had a 15% incidence of hepatocellular neoplasms. Kimura and Baba (*4*) also noted a higher incidence of hepatic neoplasms in female than in male Donryo rats. Sex difference in the incidence of PCB-induced hepatocarcinogenesis may be related to sex-linked differences in enzymatic activation and deactivation of carcinogens as proposed for acetylaminofluorine hepatocarcinogenicity (*19*), or presence of androgens or estrogens which compete for the carcinogen for metabolism as proposed for benzopyrene (*20*), aflatoxin (*21*) or dimethylbenzanthracene (*22*) hepatocarcinogenicity.

Adenofibrosis consists of glandular structures lined by mucin-secreting columnar or cuboidal cells and surrounded by layers of connective tissue. An electron microscopic study identified the lesion as intestinal metaplasia with goblet cells, enterochromaffin cells, and Paneth cells (*23*). The lack of GGT activity in adenofibrosis also suggests the lesion is quite distinct from simple cholangioma or cholangiocarcinoma, both being strongly positive for GGT (*24*).

The GGT assays were performed in Henry Pitot's laboratory at McArdle Cancer Research Institute.

This work was supported in part by NIH Grant CA22140, the Veterans Administration, and the Graduate School of the University of Wisconsin, Madison, WI.

Portions of this paper have been published in abstract form (*25–29*).

REFERENCES

1. Kimbrough, R. D., Linder, R. E., and Gaines, T. B. Morphological changes in livers of rats fed polychlorinated biphenyls. Light microscopy and ultrastructure. Arch. Environ. Health 28: 354–392 (1972).
2. Kimbrough, R. D., Squire, R. A., Linder, R. E., Strandberg, J. D., Montali, R. J., and Burse, V. M. Induction of liver tumors in Sherman strain female rats by polychlorinated biphenyl Aroclor 1260. J. Natl. Cancer Inst. 55: 1453–1459 (1975).
3. Ito, N., Nagasaki, H. J., Makiura, S., and Arai, M. Histopathological studies on liver tumorigenesis in rats treated with polychlorinated biphenyls. Gann 65: 545–549 (1974).
4. Kimura, N. T., and Baba, T. Neoplastic changes in the rat liver induced by polychlorinated biphenyl. Gann 64: 105–108 (1973).
5. Calandra, J. C. Summary of toxicological studies on commercial PCBs. In: Proceedings of the 1975 National Conference on Polychlorinated Biphenyls, Chicago, EPA-560/6-75-004, Environmental Protection Agency, Washington D.C., 1976, pp. 35–42.
6. Gross, L., and Dreyfuss, Y. Spontaneous tumors in sprague-Dawley and Long-Evans rats and in their F hybrids: carcinogenic effect of total body x-irradiation. Proc. Natl. Acad. Sci. (U.S.) 76: 5910–5913 (1970).
7. Rutenberg, A. M., Kim, H., Fischbein, J. W., Hanker, J. S., Wasserkrug, H. L., and Seligman, A. J. Histochemical and ultrastructural demonstration of gamma-glutamyl transpeptidase activity. J. Histochem. Cytochem. 17: 517–522 (1969).
8. Stewart, H. C., Keysser, C. H., Lombard, L. S., Montali, R. J., and Williams, G. M. Histologic typing of liver tumors of the rat. J. Natl. Cancer Inst. 64: 179–206 (1980).
9. Schauer, A., and Kunze, E. Tumours of the liver. In: Pathology of Tumours in Laboratory Animals, Vol. 1, Part 2. Inter. Agency for Research on Cancer, Lyon 1976, pp. 41–72.
10. Kimura, N. T., Kanematsu, T., and Baba, T. Polychlorinated biphenyl(s) as a promotor in experimental hepatocarcinogenesis in rats. Z. Krebsforsch. 87: 257–266 (1976).
11. Nishizumi, M. Effect of phenobarbital, dichlorodiphenyltrichloroethane, and polychlorinated biphenyls of diethylnitrosamine-induced hepatocarcinogenesis. Gann 70: 835–837 (1979).
12. Tatematsu, M., Nakanishi, K., Murasaki, G., Miyata, Y., and Hirose, M. Enhancing effect of inducers of liver microsomal enzymes on induction of hyperplastic liver nodules by *N*-2-fluorenylacetamine in rats. J. Natl. Cancer Inst. 63: 1411–1416 (1979).
13. Preston, B. D., Van Miller, J. P., Moore, R. W., and Allen, J. R. Promoting effects of polychlorinated biphenyls (Aroclor 1254) and polychlorinated dibenzofuran-free Aroclor 1254 on diethylnitrosamine-induced tumorigenesis in the rat. J. Natl. Cancer Inst. 66: 509–515 (1981).
14. Pereira, M. A., Herren, S. L., Britt, A. L., and Khoury, M. M. Promotion by polychlorinated biphenyls of enzyme-altered foci in rat liver. Cancer Letters 15: 185–190 (1982).
15. Pitot, H. C., and Sirica, A. W. The stages of initiation and promotion in hepatocarcinogenesis. Biochim. Biophys. Acta 605: 191–215 (1980).
16. Norback, D. H., Seymour, J. L., Knieriem, K. M., Peterson, R. E., and Allen, J. R. Biliary metabolites of 2,5,2′,5′-tetrachlorobiphenyl in the rat. Res. Commun. Chem. Pathol. Pharmacol. 14: 527–533 (1976).
17. McCann, J., and Ames, B. N. Detection of carcinogens as mutagens in the *Salmonella*/microsome test: assay of 300 chemicals: Discussion. Proc. Natl. Acad. Sci. (U.S.) 73: 950–954 (1976).
18. Shahin, M. M., Andrillon, P., Goetz, N., Bore, P., Bugaut, A., and Kalopissis, G. Studies on the mutagenicity of *p*-phenylenediamine in *Salmonella typhimurium*. Presence of PCB's in rat-liver microsomal fraction induced by Aroclor. Mutat. Res. 68: 327–336 (2279).
19. Miller, J. A. Carcinogenesis by chemicals: an overview—G.H.A. Clowes Memorial Lecture. Cancer Res. 30: 559–576 (1970).
20. Nebert, D. W., Bausserman, L. L., and Bates, R. R. Effect of 17-O-estradiol and testosterone on aryl hydrocarbon hydroxylase activity in mouse tissues *in vitro* and in cell culture. Int. J. Cancer 6: 470–480 (1970).
21. Tulunay, F. C., and Turker, R. K. Steroid sex hormones as inhibitors of aflatoxin metabolism in liver homogenates. Specialia 15: 929–931 (1972).
22. Booth, J., Keysell, G. R., and Sims, P. Effect of cestradiol on the *in vitro* metabolism of 7,12-dimethylbenz(a)anthracene and its hydroxymethyl derivatives. Biochem. Pharmacol. 23: 734–744 (1974).
23. Terao, K., and Nakano, M. Cholangiofibrosis induced by short-term feeding of 3′-methyl-4-(dimethylamino)azobenzene: an electron microscopic observation. Gann 65: 249–260 (1974).
24. Harada, M., Okabe, K., Shibata, K., Masada, H., Miyata, K., and Enomoto, M. Histochemical determination of increased activity of gamma-glutamyl transpeptidase in rat liver during heptacarcinogenesis. Acta Histochem. Cytochem. 9: 168–179 (1976).
25. Cihla, H. P., Weltman, R. H., Pitot, H. C., and Norback, D. H. Sex difference in the acquisition of gamma-glytamyl transpeptidase (GGT) positive foci in the liver of Sprague-Dawley rats fed polychlorinated biphenyls (PCB). Toxicologist 1: 131 (1981).
26. Cihla, H. P., Weltman, R. H., Pitot, H. C., and Norback, D. H. The gamma-glutamyl transpeptidase (GGT) activity of liver lesions in rats exposed to Aroclor 1260. Toxicologist 2: 97 (1982).
27. Weltman, R. H., and Norback, D. H. Sequential, light and electron microscopic analysis of hepatocellular carcinoma induced by Aroclor 1260. Toxicologist 1: 65 (1981).
28. Weltman, R. H., and Norback, D. H. The light and electron microscopic evaluation of cholangiocellular neoplasms in the rat liver following chronic Aroclor 1260 exposure. Toxicologist 2: 100 (1982).
29. Weltman, R. H., and Norback, D. H. Development of hepatocellular and cholangiocellular neoplasms in the livers of male and female Sprague-Dawley rats after chronic administration of Aroclor 1260. Fed. Proc. 41: 446 (1982).