


MASTER

THE CARCINOGEN ASSESSMENT GROUP'S

RISK ASSESSMENT OF

AVADEX (DIALLATE AND TRIALLATE)



Roy E. Albert, M.D.
Chairman

MAY 7 1979

PARTICIPATING MEMBERS

Elizabeth L. Anderson, Ph.D.
Bernard H. Haberman, D.V.M., M.S.
Richard N. Hill, M.D., Ph.D.*
Charalingayya Hiremath, Ph.D.
Mary Christelle Macaluso, R.S.M., Ph.D.*
Robert E. McGaughy, Ph.D.
Steven M. Miller, M.S.
Melvin D. Reuber, M.D.*
Wade T. Richardson, J.D.*
Dharm V. Singh, D.V.M., Ph.D.
Todd W. Thorslund, Ph.D.
Adrienne J. Zahner, Ph.D.

*Participated in preliminary (not final) report.

TABLE OF CONTENTS

	Page
I. Summary and Conclusions	i-iii
II. Metabolism and Mutagenesis	1
III. Mouse Carcinogenesis Studies	4
A. Innes Study (Oral)	4
B. Intraperitoneal Carcinogenicity Study in Mice (Boots)	10
C. Dermal Carcinogenesis Study in Mice (Boots)	11
D. Skin Tumor-Initiating Study in Mice (Boots)	12
E. Skin Tumor-Promoting Study in Mice (Boots)	13
F. Innes Mouse Study (Subcutaneous)	13
IV. Rat Carcinogenesis Studies	14
A. Litton Bionetics Study	14
B. Industrial Bio-Test Study (Diallate)	18
C. Industrial Bio-Test Study (Triallate)	23
V. Summary	27
VI. Quantitative Risk Assessment	30
VII. References	39
VIII. Appendix 1	
Report on Histopathologic Studies of Monsanto Triallate (Avadex-BW) Experiment on Charles River Albino CD Rats, by I.N. Dubin, M.D.	

NOTICE

THIS DOCUMENT CONTAINS INFORMATION THAT MAY BE PROTECTED FROM PUBLIC DISCLOSURE UNDER SECTION 10 OF THE FEDERAL INSECTICIDE, FUNGICIDE, AND RODENTICIDE ACT. ANY UNAUTHORIZED DISCLOSURE OF THIS INFORMATION MAY RESULT IN CRIMINAL PENALTIES AND/OR DISCIPLINARY ACTION. ANY REQUEST FOR RELEASE OF THIS DOCUMENT SHOULD BE REFERRED TO: Charles Colledge, Program Support Division, Office of Pesticide Programs, Phone - 426-2680

I. SUMMARY AND CONCLUSIONS

The carcinogenic potential of Avadex (Diallate) was investigated in two studies in mice and two studies in rats, while that of Avadex BW (Triallate) was investigated in one rat study.

In the Innes study, Diallate treatment resulted in a statistically significant increase in hepatomas in two strains (X and Y)¹ of male mice compared with the matched (vehicle) control group ($p=1.6 \times 10^{-6}$ and $p=1.4 \times 10^{-3}$, respectively), the negative (without vehicle) control group ($p=1.2 \times 10^{-5}$ and $p=.018$, respectively), and the pooled negative control groups ($p=2.0 \times 10^{-8}$ and $p=2.3 \times 10^{-6}$, respectively). Female mice of strain X had a statistically significant increase of hepatomas compared with the pooled control group ($p=.023$). In this study, there was also an increase in pulmonary adenomas in treated males of strain X compared with the pooled ($p=.041$) and matched ($p=.051$) control groups; and in total tumor incidence in treated males of strains X and Y ($p=2.5 \times 10^{-7}$ and $p=2.9 \times 10^{-3}$, respectively) and females of strain X ($p=.021$) compared with the appropriate matched control groups.

In the Boots study of female mice (from Schofiel) given Diallate intraperitoneally, there was no statistically significant tumor incidence at individual organ sites.

1) Strain X is (C57BL/6 x C3HAnf)F1 and strain Y is C57BL/6 x AKR)F.


In the Litton Bionetics rat study, there was an increased incidence of total tumors in the high dose (300 ppm) male group compared with the pooled control group ($p=.032$) and with one of the two matched control groups ($p=.023$). There was no significant tumor incidence at any specific anatomical site. Females of the high dose group had an increase of carcinomas compared with pooled controls ($p=.042$), but neither of the treated female groups had an increased incidence of total tumors or of any specific tumors by anatomical site.

The Industrial Bio-Test rat study of Diallate showed an increased incidence ($p=.021$) of benign mammary gland tumors in females treated with 100 ppm, but there was no other increase of specific tumors (by anatomical site) or of total tumors in treated rats of both sexes.

The only available data for Triallate is from one rat study performed by Industrial Bio-Test. The results did not indicate a significant tumor incidence in either sex. However, Triallate is structurally very similar to Diallate, and both compounds are mutagenic (the latter being a more potent mutagen). There is a paucity of information available regarding the mammalian metabolism of Diallate and Triallate. If it were demonstrated that Triallate metabolizes to Diallate in vivo, or that Triallate and Diallate share common metabolites that are carcinogenic, then it could be suggested that carcinogenic risk might also be associated with exposure to Triallate. Further metabolism studies should be conducted to clarify this issue.

In summary, there is significant evidence that Diallate may be a human carcinogen. The evidence concerning carcinogenic potential of Triallate is negative. However, because of similar structure to Diallate and positive mutagenicity data, Triallate should be studied further.

The quantitative risk assessment for Diallate was based on the Innes feeding study in mice, where the end-point utilized was hepatoma incidence in male mice of strain X. Utilizing a one-hit model, the risk associated with all food uses considered together was about 1.5×10^{-6} , which would mean an excess of about 5 cancers per year in the U.S. A risk to applicators as high as 1×10^{-3} was estimated to be associated with dermal exposure, but the number exposed was small.

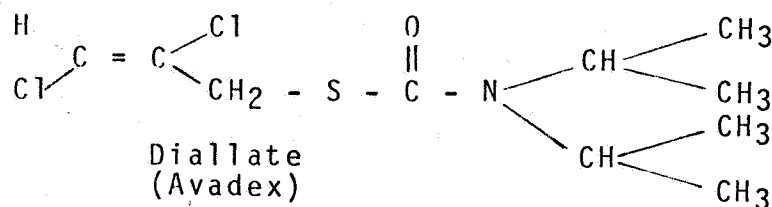
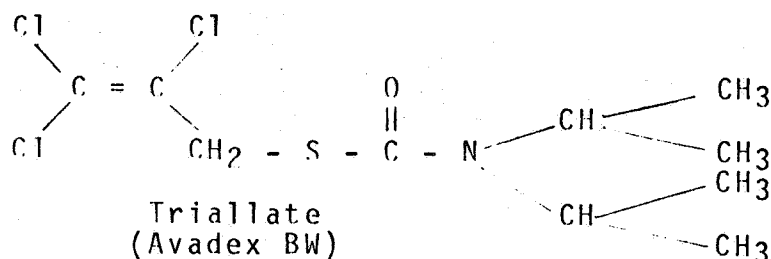


II. METABOLISM AND MUTAGENESIS

A) METABOLISM STUDY

A study of the metabolic fate of radioactively labeled Avadex injected intraperitoneally in rats revealed that, with 88% of the administered compound radioactively accounted for in 48 hours after injection, 61% appeared in urine, 19% in feces and 8% as exhaled CO₂.(1) The urinary metabolites were not identified.

There is no further information available regarding mammalian metabolism of Diallate or Triallate (structures shown below). This is an important aspect because Triallate is structurally similar to Diallate and, yet, the one oncogenicity study on Triallate was negative compared with positive oncogenicity data for Diallate. If, in fact, it were demonstrated that Triallate metabolizes to Diallate in vivo, or if Triallate and Diallate had common metabolites which are carcinogenic, then it could be suggested that carcinogenic risk might also be associated with exposure to Triallate. Further metabolism studies would be necessary to clarify this issue.



B) MUTAGENESIS

Dominant lethal tests of Avadex (diallate) and Avadex BW (triallate) in albino Charles River mice were performed by Industrial Bio-Test Laboratories. (2) Each compound was injected intraperitoneally with corn oil into groups of male mice. Each of the two studies was performed with a negative control group using Metepo (tris-1-(2-methyl)-azidiny] phosphine oxide). After treatment, the males were mated sequentially with untreated females during a six week period and the females were examined in an early stage of pregnancy for the number of implanted embryos and number of embryonic deaths. Avadex was treated at doses of 100 and 200 mg/kg body weight, and avadex BW at 200 and 400 mg/kg body weight.

The results of these tests were that treated groups did not show any significant decrease in the number of viable offspring compared with the negative control groups whereas the positive control groups did show a significant reduction in the number of viable offspring, as expected. Therefore, the compounds do not cause dominant lethal mutations in treated males under the conditions of the test.

Mutagenesis tests were performed by Andersen, et al. (10) on a series of 110 herbicides including diallate and triallate in Salmonella typhimurium and on 35 herbicides including triallate in a T4 bacteriophage/E. coli test system. Neither system included metabolic activation and the concentrations were not stated. None of the 110

compounds induced a significant number of mutations in the Salmonella tests, and only 4 compounds, not including triallate, were marginally significant in the T4/E. coli test. Although these experiments were negative, the inclusion of a metabolic activation system, which is the current accepted practice might produce a positive result. Therefore, the negative result must be considered tentative.

Mutagenesis tests were performed in Salmonella typhimurium by De Lorenzo, et al. on a series of 20 carbamate herbicides and fungicides including diallate and triallate (11), and by Sikka and Florczyk on diallate and triallate (12). Both studies were performed with and without metabolic activation. Diallate and Triallate induced a significant number of mutations in strains TA 1535 and TA 100 with metabolic activation. DeLorenza, et al. reported a linear dose response curve for both compounds. In both studies, a significant number of mutations was not induced in these strains without metabolic activation, nor in strains TA 1537, TA 1538, and TA 98 with or without metabolic activation. The results indicate that these compounds are metabolized into one or more metabolites which possess potent base pair substitution inducing capabilities. Diallate was a considerably more potent mutagen than triallate in both studies although triallate was clearly mutagenic. De Lorenzo et al. postulate that the 2-chloro-allyl group, common to the 2 mutagenic compounds, is responsible for the observed effect. Its chemical structure is very similar to known mutagenic and carcinogenic compounds structurally related to vinyl chloride such as vinylidene chloride which has the dichloroethenyl structure found in triallate(1).

III. MOUSE CARCINOGENESIS STUDIES

A. Innes Study (Oral)

The maximal tolerated dose of Avadex (Diallate) was given to two hybrid strains of mice (C57BL/6 x C3HAnf) F1 designated as "strain X" and (C57BL/6 x AKR)F designated as "strain Y" mice.(3) There were 18 treated mice and 18 untreated controls of each strain and each sex. Two hundred fifteen mg/kg body weight was given in gelatin daily by stomach tube beginning when the mice were 7 days of age. After the mice were weaned at 28 days of age, 560 ppm Avadex was mixed directly in the diet and provided ad libitum. Treatment was continued for 84-86 weeks. Pooled controls represent four different untreated control groups, each in a separate room, and an additional control group given 0.5% gelatin suspension (vehicle).

Post mortem observations included thorough external examination and examination of the thoracic and abdominal cavities, with histologic examination of major organs and of all grossly visible dissected. The cranium and thyroid glands were not dissected. Blood smears were examined of all mice with splenomegaly or lymphadenopathy.

There were significantly elevated incidences of hepatomas in livers of male mice of Strain X and Strain Y when compared with either their respective matched (vehicle) control group ($p = 1.6 \times 10^{-6}$ and $p = 1.4 \times 10^{-3}$, respectively), negative (without vehicle) control group ($p = 1.2 \times 10^{-5}$ and $p = .018$ (significant at $p \leq .05$ level),

respectively), or pooled negative control groups ($p = 2.0 \times 10^{-8}$ and $p = 2.3 \times 10^{-6}$, respectively). There was a statistically significant incidence of hepatomas in female mice of strain X when compared with the pooled control group only ($p = .023$, significant at $p \leq .05$ level). The data is indicated in Table 1. Metastases were not observed. However, in this particular study, the mice were killed after 18 months, rather than allowing the mice to survive 2 years or more, a time long enough for metastases to have probably occurred.

Table I LIVER TUMORS (HEPATOMAS) IN MICE INGESTING
 AVADEX (DIALATE)

Strain	Dose Group	Tumors of the Liver	
		Male	Female
X	Matched control (vehicle)	0/16 (p = 1.6×10^{-6})*	0/16 (p = .242)
X	Negative control	1/17 (p = 1.2×10^{-5})*	0/18 (p = .214)
X	Pooled control	8/79 (p = 2×10^{-8})*	0/87 (p = .023)**
X	560 ppm	13/16	2/16
Y	Matched Control (vehicle)	1/18 (p = 1.4×10^{-3})*	0/17 (p = .469)
Y	Negative Control	3/18 (p = .018)**	0/17 (p = .469)
Y	Pooled Control	5/90 (p = 2.3×10^{-6})*	1/82 (p = .287)
Y	560 ppm	10/18	1/15

The numbers in parentheses are the p values for statistical significance of the tumor incidence in the treated group compared with the indicated control group (Fisher Exact test).

* indicates statistically significant at $p \leq .01$ level;

** indicates statistically significant at $p \leq .05$ level.

The hepatoma incidence in Avadex-treated mice compared to that in the positive control group treated with ethyl carbamate is shown below.

Treatment Group	<u>Strain X</u>		<u>Strain Y</u>	
	Male	Female	Male	Female
Avadex	13/16 (81%)	2/16 (13%)	10/18 (56%)	1/15 (7%)
Ethyl Carbamate (Positive Control)	8/20 (40%)	12/23 (52%)	14/22 (64%)	5/19 (26%)

The data for pulmonary tumors shown in Table 2 indicates a borderline statistically significant increase of pulmonary adenomas in the Diallate-treated males of strain X compared with the matched (vehicle) control group ($p = .051$) and with the pooled control groups ($p = .041$).

Table 2 LUNG TUMORS IN MICE INGESTING AVADEx (DIALLATE)

	Dose Group	<u>Strain X</u>		<u>Strain Y</u>	
		Male	Female	Male	Female
Pulmonary Adenoma	Matched Control	0/16*	0/16	2/18	1/17
		0/16	0/16	0/18	0/17
Pulmonary Carcinoma	Matched Control	0/16	0/16	0/18	0/17
		0/16	0/16	0/18	0/17
Pulmonary Adenoma	Negative Control	2/17	1/18	2/18	0/17
		0/17	0/18	0/18	0/17
Pulmonary Carcinoma	Negative Control	0/17	0/18	0/18	0/17
		0/17	0/18	0/18	0/17
Pulmonary Adenoma	Pooled Control	5/79**	3/87	10/90	3/82
		0/79	0/87	0/90	0/82
Pulmonary Carcinoma	Pooled Control	0/79	0/87	0/90	0/82
		0/79	0/87	0/90	0/82
Pulmonary Adenoma	560 ppm	4/16	2/16	4/18	1/15
		0/16	0/16	0/18	0/15
Pulmonary Carcinoma	560 ppm	0/16	0/16	0/18	0/15
		0/16	0/16	0/18	0/15

* p = .051 (Fisher Exact Test) for the incidence of pulmonary adenomas in the treated group compared with the matched control.
 ** p = .041 (Fisher Exact Test) for the incidence of pulmonary adenomas in the treated group compared with the pooled control.

There was a statistically significant incidence of total tumors in the treated males of both strains X and Y ($p = 2.5 \times 10^{-7}$ and $p = 2.9 \times 10^{-3}$, respectively), and in the treated females of strain X ($p = .021$) when compared to the appropriate matched control group (Table 3).

Table 3 INCIDENCE OF TOTAL TUMORS IN MICE INGESTING AVADEX (DIALATE)

Strain	Dose Group	Tumors in any Organ	
		Male	Female
X	Matched Control	0/16(0%)	0/16(0%)
X	Pooled Control	22/79(27%)	8/87(9%)
X	560 ppm	14/16(88%)*	5/16(31%***)
Y	Matched Control	3/18(17%)	2/17(12%)
Y	Pooled Control	16/90(18%)	7/82(8%)
Y	560 ppm	12/18(67%)**	2/15(13%)

The following p values (Fisher Exact Test) were calculated relative to matched control data.

* $p = 2.5 \times 10^{-7}$, ** $p = 2.9 \times 10^{-3}$, *** $p = .021$

In summary, Diallate treatment resulted in a statistically significant increase of hepatomas in male mice of both strains X and Y relative to their respective matched control, negative control and pooled control groups; and in female mice of strain X when compared with the pooled control group. There was a statistically significant increase of lung adenomas in treated strain X males compared with pooled controls, and a borderline increase compared with matched controls. A statistically significant increase of total tumors (all organs) occurred in treated mice of strain X (both sexes) and male mice of strain Y compared with the respective matched controls.

B. Intraperitoneal Carcinogenicity Study in Mice (Boots)

Female albino mice (obtained from Schofiel), weighing 18-29 grams, were given weekly intraperitoneal injections of 5 mg of the active ingredient of Avadex (Diallate) CP-15336 (2% suspended in 10% gum acacia) for 10 weeks.(5) There were 50 mice per group. Controls received the vehicle alone. Mice ingested Oxoid modified diet 41B for the first 4 months and Oxoid breeding diet for the remainder of the study. Twenty mice were killed at the end of 37 weeks and the remainder after 72 weeks.

Necropsies were done on mice that died or were killed. Superficial glands, liver, spleen, kidney, adrenal, stomach, urinary bladder, thymus and skin were examined grossly. Abnormal tissues were examined histologically. Histologic

sections of lungs were routinely performed. Although tumors were more malignant in treated mice, there was no statistically significant increase of any tumor type by anatomical site or of total tumors in the treated mice compared with controls.

C. Dermal Carcinogenesis Study in Mice (Boots)

Female albino mice (obtained from Schofiel) weighing 18-29 grams, were given weekly skin applications of 75 mg of the active ingredient of Avadex, CP- 15336 (30% in acetone) for up to 76 weeks and killed. (6) There were 50 mice per group. Controls were the mice from a lung tumor study that received intraperitoneal injections of gum acacia.² Mice ingested Oxoid modified diet 41B for the first 4 months and Oxoid breeding diet for the remainder of the study.

The hair of the back, from the scapula to the tail, was clipped before treatment and at intervals whenever necessary. The chemical solutions, calibrated by pipette at 0.25 ml per application, were spread as evenly as possible over the clipped surface.

Necropsies were done on mice that died or were killed. Superficial glands, liver, spleen, kidney, adrenals, stomach, urinary bladder, thymus and skin were examined grossly. Abnormal tissues were examined histologically. Histologic sections of lungs were routinely performed.

-
- 1) Avadex consists of 41.99% CP15336, 54.03% Panola heavy aromatic naphtha, and 4.00% of emcol, AD4-20.
 - 2) Twenty were killed at the end of 37 weeks, and are not included in these results.

There was some indication that tumors occurring in treated mice were more malignant (metastatic) than in control mice, but there was no statistically significant increase of tumors reported for any organ site.

D. Skin Tumor-Initiating Study in Mice (Boots)

Female albino mice (obtained from Schofiel) weighing between 18-29 grams, were given weekly skin applications of 75 mg. of the active ingredient of Avadex (Diallate), CP15336, (30% in acetone) for 10 weeks.(5) Another group of mice received weekly gastric intubation 15 mg CP15336 (6% in 10% gum acacia) for 10 weeks. The mice then received weekly skin applications of 0.25% croton oil for 25 weeks, and were killed at 37 weeks after the study began. The negative control was given acetone and the positive control consisted of urethane followed by croton oil. There were 30 mice in each group.

During the study "characteristic signs of CP15336 toxicity were seen in two mice treated with skin applications and in six mice dosed orally,..."

There were no significant differences in the numbers of mice with papillomas of the skin or forestomach between the controls and Avadex (Diallate)-treated mice.

It was concluded that Avadex was not a tumor-initiating chemical when applied to the skin or forestomach under the conditions of this study.

G. Skin Tumor-Promoting Study in Mice (Boots)

Female albino mice (obtained from Schofiel) weighing 18-20 grams were given a single skin application of 150 micro-gram dimethylbenzanthracene (DMBA) in 0.1 ml acetone.(5) Three weeks later 20 applications of 75 mg avadex (30% in 0.25 ml acetone) were made at weekly intervals. A second group of mice received DMBA followed by acetone, and a third group received DMBA followed by croton oil. There were 20 mice in each group. Mice were killed 1 week after treatment was completed.

Skin tumors were not observed in mice painted with Avadex (Diallate) or acetone. There was a high incidence of skin tumors in the positive control mice.

It was concluded that Avadex was not a skin tumor-promoting chemical when applied to the skin under the conditions of this study.

F. Innes Mouse Study (Subcutaneous)

Two hybrid strains of mice, (C57BL/6 x C3HAnf)F1 designated as "strain A" and (C57BL/6xAKR)F1 designated as "strain B" mice were used (5). Male and female mice, 18 per group, were given a single subcutaneous injection of 1000 mg/kg body weight Avadex (Diallate) in corn oil on the 28th day of life and killed after 80 weeks. Control mice received corn oil only. The diet consisted of laboratory chow.

Tumors were not increased in mice given a single subcutaneous injection of Avadex.

IV. RAT CARCINOGENESIS STUDIES

A. Litton Bionetics Study

Avadex (Diallate), was administered in the diet to 26 male and 26 female Sprague-Dawley rats for 18 months and killed after 24 months.(7) The treated rats, divided by sex, were also divided into dosage groups, totaling 4 treated groups. The high dose, 300 ppm, was intended to be the maximal amount that the rats could tolerate for that period of time. The low dose was one-half the high dose. Two groups of 32 males and two groups of 32 females received no treatment. Necropsies and complete histopathologic examinations were performed on all rats.

Average survival times for the male rats ingesting the high dose of Diallate were less than male rats in the other groups. One female rat given the high dose was killed at 28 weeks because of carcinoma of the mammary gland.

SURVIVAL TIMES (WEEKS) FOR MALES AND FEMALES INGESTING AVADEx

Dose	Females Average (range)	Males Average (range)
0	82.3 (44-93)	97.7 (63-104)
0	103.0 (94-104)	99.0 (45-104)
Low Dose	90.3 (47-104)	96.7 (57-104)
High Dose	91.3 (28-104)	83.5 (54-104)

There was a statistically significant increase in total malignant tumors in the male rats of the high dose group when compared with the pooled control group ($p = .032$), and with one of the matched control groups (10/26 high dose vs. 4/32 control, $p = .023$) (Table 4). There was no statistically significant increase of total tumors compared with the other matched control group. An analysis of the tumor data by anatomical site revealed no statistically significant tumor incidence in the treated rats at any organ site.

Female rats ingesting the high dose of Avadex (Diallate) had a statistically significant increase ($p \leq .042$) of carcinomas: i.e., there were 5/26 (19%) in the treated rats compared with 3/64 (5%) in the pooled controls (Table 6). There was no statistical significance when compared with either matched control group (Table 5). There was no statistically significant increase in total tumors (carcinomas and sarcomas) in the treated female rats at either dose when compared to pooled or matched controls (Table 5). When the data was analyzed by anatomical site, there was no statistically significant increase in tumor incidence at any site.

In summary, male rats ingesting the high dose of Avadex (Diallate) developed a significantly increased incidence of malignant tumors when compared with pooled controls. In female rats given the high dose of Avadex (Diallate), the

incidence of carcinomas was significantly increased when compared with pooled controls. When the tumor data was analyzed by anatomical site, there were no statistically significant increases in tumors of any site in treated male or female rats relative to their respective controls.

Table 4 INCIDENCE OF MALIGNANT TUMORS IN MALE RATS
INGESTING AVADDEX (DIALLATE)

Dose Group	No. of Rats with Carcinomas	No. of Rats with Sarcomas ^{a)}	Total No. of Rats with Malignant Tumors ^{b)c)}
Matched Control	2/32 (6%)	2/32 (6%)	4/32 (13%)*
Matched Control	2/32 (6%)	5/32 (16%)	7/32 (22%)
Pooled Control	4/64 (6%)	7/64 (11%)	11/64 (17%)**
Low Dose	3/26 (12%) ^{d)}	1/26 (4%)	4/26 (15%)
High Dose	4/26 (15%)	4/26 (15%)	10/26 (38%) ^{e)}

-
- a) Gliomas and leukemias were counted as sarcomas.
 - b) Rats with carcinomas did not have sarcomas.
 - c) Corrected for survival.
 - d) Two of these rats with carcinomas had metastases (carcinoma of the prostate metastatic to lung and lymph nodes; islet cell carcinoma of the pancreas with metastases to the heart).
 - e) The total incidence of 10/26 includes 2 unclassified malignant tumors in the subcutaneous tissue.

* The tumor incidence in the high dose group compared to this matched control group is statistically significant ($p = .023$) (Fisher Exact Test).

** The tumor incidence in the high dose group compared to the pooled control group is statistically significant ($p = .032$) (Fisher Exact Test).

Table 5 INCIDENCE OF MALIGNANT TUMORS IN FEMALE RATS
INGESTING AVADEX (DIALATE)

Dose Group	No. of Rats with Carcinomas	No. of Rats with Sarcomas ^{a)}	Total No. of Rats with Malignant Tumors ^{b)}
0	3/32 (9%)	2/32 (6%)	5/32 (16%)
0	0/32 (0%)	2/32 (6%)	2/32 (6%)
Low Dose	2/26 (8%) ^{c)}	2/26 (8%)	4/26 (15%)
High Dose	5/26 (19%)	0/26 (0%)	5/26 (19%)

a) Gliomas and leukemias were counted as sarcomas.

b) Rats with sarcomas did not have carcinomas.

c) The 2 rats with carcinomas of the mammary gland had metastases to the lungs.

Table 6 INCIDENCE OF MALIGNANT TUMORS IN FEMALE RATS
INGESTING AVADEX (DIALATE)

Dose Group	No. of Rats with Carcinomas	No. of Rats with Sarcomas	Total No. of Rats with Malignant Tumors
0	3/64 (5%)	4/64 (6%)	7/64 (11%)
High Dose	5/26 (19%) (p = .042)*	0/26 (0%)	5/26 (19%)

* Fisher Exact Test

B. Industrial Bio-Test Study (Diallate)

A chronic oral toxicity study was carried out with Charles River albino rats. (9)4) Male and female rats, 50 in each group ingested 0, 50, 100 or 200 ppm of Avadex Technical (Diallate) in dry, pulverized Purina rat chow for 24-1/2 months. 5)6) Control rats were the same as for the Avadex BW (Triallate) study. Rats were housed individually in metal cages. Food and water were administered ad libitum.

Food consumption and body weights were recorded, as well as hematology, selected blood chemistries and urinalyses at periodic intervals.

Complete gross necropsies were carried out on all rats found dead except for advanced autolysis, and on all rats killed. Terminal weights were taken of brain, gonads, heart, kidney, liver and spleen. Detailed histopathological examinations were done on "selected animals found dead, and on all remaining animals at the 24 month sacrifice." All neoplasms and tissues with suspected neoplastic lesions were studied.

Body weight gains were slightly less for female and male rats ($p \leq .05$) ingesting 200 ppm Avadex (Diallate) than the control rats up to the 10th week. Food consumption of treated rats was similar to that of the untreated rats.

Mortality was increased in the female rats treated with the highest dose (200 ppm) of Avadex (Diallate).

4. Charles River Breeding Laboratories, Inc., Wilmington, Mass.
5. CP 23436, Lot Va. XHE-51, 95.3
6. Ralston-Purina Co., St. Louis, Mo.

MORTALITY (WEEKS) FOR MALE RATS INGESTING DIALLATE^{a/}

Dose (ppm)	1-51	52-64	65-77	78-90	91-105	%Lead
0	1/50(2%)	3/50(6%)	10/50(20%)	7/50(14%)	13/50(26%)	34/50(68%)
50	1/50(2%)	5/50(10%)	11/50(22%)	11/50(22%)	13/50(26%)	41/50(82%)
100	5/50(10%)	2/50(4%)	5/50(10%)	13/50(26%)	10/50(20%)	34/50(68%)
200	2/50(4%)	3/50(6%)	7/50(14%)	10/50(20%)	15/50(30%)	37/50(74%)

a/ Number of rats dying in the stated interval.

MORTALITY (WEEKS) FOR FEMALE RATS INGESTING DIALLATE^{a/}

Dose (ppm)	1-51	52-64	65-77	78-90	91-105	%Dead
0	1/50 (2%)	0/50 (0%)	6/50 (12%)	9/50 (18%)	12/50 (24%)	24/50 (48%)
50	0/50 (0%)	2/50 (4%)	3/50 (6%)	8/50 (16%)	17/50 (34%)	30/50 (60%)
100	2/50 (4%)	1/50 (2%)	4/50 (8%)	10/50 (20%)	15/50 (30%)	32/50 (64%)
200	3/50 (6%)	1/50 (2%)	10/50 (20%)	7/50 (14%)	17/50 (34%)	38/50 (76%)*

a/ Number of rats dying in the stated interval.
 * Increased mortality is statistically significant
 (p = .0034, Fisher Exact Test).

There was no statistically significant increase in total tumors (benign and malignant) nor in tumors of any anatomical site in treated male rats compared with controls (Table 7).

Table 7 INCIDENCE OF BENIGN AND MALIGNANT TUMORS IN MALE RATS INGESTING DIALLATE^{a/}

Dose Group (ppm)	No. of Rats with Benign Tumors	No. of Rats with Malignant Tumors ^{a)}	Total No. of Rats with Tumors ^{b)}
0	1/50 (2%)	4/50 (8%)	5/50 (10%)
50	0/50 (0%)	7/50 (14%)	7/50 (14%)
100	2/49 (4%)	4/49 (8%)	6/49 (12%)
200	1/50 (2%)	6/50 (12%)	7/50 (14%)

a) Number of rats with endocrine tumors are not included.

b) Rats with both benign and malignant tumors were counted once in the column with malignant tumors.

INCIDENCE OF CARCINOMAS AND SARCOMAS IN MALE RATS INGESTING DIALLATE^{a)}

Dose Group (ppm)	No. of Rats with Carcinomas	No. of Rats with Sarcomas	Total No. of Rats with Malignant Tumors ^{b)}
0	0/50 (0%)	4/50 (8%)	4/50 (8%)
50	3/50 (6%)	4/50 (8%)	7/50 (14%)
100	1/49 (2%)	3/49 (6%) ^{c)}	4/49 (8%)
200	2/50 (4%)	4/50 (8%)	6/50 (12%)

a) Number of rats with endocrine tumors are not included

b) Rats with both benign and malignant tumors were counted once as malignant.

c) One rat had metastatic fibrosarcoma to the lung and liver, another to the lung. No primary sarcoma was found in the two rats.

There was an increased incidence ($p = .021$) of benign mammary gland tumors in females treated with 100 ppm of Avadex (Diallate) compared with controls (Table 8). With the exception of the benign mammary tumors, there was no statistically significant increase in tumors of any other anatomical site or in total tumors in the treated females.

Table 8 INCIDENCE OF BENIGN AND MALIGNANT TUMORS OF THE MAMMARY GLAND IN FEMALE RATS INGESTING DIALLATE ^{a/}

Dose Group (ppm)	No. of Rats with Benign Tumors	No. of Rats with Malignant Tumors	Total No. of Rats with Tumors
0	14/50 (28%)	5/50 (10%)	19/50 (38%)
50	19/49 (39%)	4/49 (8%)	23/49 (47%)
100	24/48 (50%)*	5/48 (10%)	29/48 (60%)*
200	15/46 (33%)	10/46 (22%)	25/46 (54%)

a/ Some rats had both benign and malignant tumors. Those rats are counted once in the column with malignant tumors.

* $p = .021$ (Fisher Exact Test)

C. Industrial Bio-Test Study (Triallate)

A chronic oral toxicity study (8) was carried out with Charles River albino rats.¹ Male and female rats, 50 in each group, ingested 0, 50, 100 or 200 ppm of Avadex BW (Triallate) Technical in dry, pulverized Purina rat chow for 24-1/2 months.^{2,3} Control rats were the same as for the Diallate study. Rats were housed individually in metal cages. Food and water were administered ad libitum.

Food consumption and body weights were recorded, as well as hematology, selected blood chemistries and urinalyses at periodic intervals.

Complete gross necropsies were carried out on all rats found dead, except for those with advanced autolysis, and on all rats killed. Terminal weights were taken of brain, gonads, heart, kidney, liver and spleen. Detailed histopathological examinations were done on "selected animals sacrificed." All neoplasms and tissues with suspected "neoplastic lesions" were studied.

Male rats ingesting 200 ppm Avadex BW failed to gain weight during the first 3 weeks as did rats in the other groups ($p < 0.01$). Food consumption measurements disclosed that the amount of food eaten by test animals was similar to that of the controls.

The mortality data (shown on following pages) did not indicate a statistically significant difference in mortality between the treated and control groups.

- 1) Charles River Breeding Laboratories, Inc., Wilmington, Mass.
- 2) CP 23436, Lot Va XHE-51, 95.3
- 3) Ralston-Purina Co., St. Louis, Mo.

MORTALITY (IN WEEKS) FOR MALE RATS INGESTING AVADEx-BW (TRIALATE)^{a/}

Dose (ppm)	1-51	52-64	65-77	78-90	91-105	%Dead
0	2/50 (4%)	3/50 (6%)	10/50 (20%)	7/50 (14%)	13/50 (26%)	34/50 (68%)
50	0/50 (0%)	4/50 (8%)	16/50 (32%)	10/50 (20%)	11/50 (22%)	41/50 (82%)
100	3/50 (6%)	7/50 (14%)	7/50 (14%)	8/50 (16%)	10/50 (20%)	35/50 (70%)
200	6/50 (12%)	3/50 (6%)	10/50 (20%)	5/50 (10%)	9/50 (18%)	33/50 (66%)

^{a/} Number of rats dying at this time.

MORTALITY (IN WEEKS) FOR FEMALES INGESTING AVADEX - BW (TRIALLATE)^a

Dose (ppm)	1-51	52-64	65-77	78-90	91-105	%Dead
0	1/50(2%)	0/50(0%)	6/50(12%)	9/50(18%)	12/50(24%)	28/50(56%)
50	2/50(4%)	2/50(4%)	9/50(18%)	5/50(10%)	11/50(22%)	29/50(58%)
100	4/50(8%)	2/50(4%)	7/50(14%)	11/50(22%)	11/50(22%)	35/50(70%)
200	1/50(2%)	2/50(4%)	4/50(8%)	12/50(24%)	13/50(26%)	32/50(64%)

a/ Number of rats dying at that time.

The tumor data did not indicate a statistically significant increase of total tumors or of tumors by anatomical site in either the treated males or females relative to their respective controls.

Dr. I.N. Dubin reviewed for the CAG all of the available slides from all animals (both sexes) in the control group and 100 ppm dose group (which showed the highest tumor occurrence). The only statistically significant tumor incidence ($p < .01$) involved pituitary chromophobe adenomas in female rats (9/22 control vs. 13/15 treated). However, as stated in his report (Appendix 1), this tumor type has a high spontaneous occurrence and, therefore, the increased incidence may not be biologically meaningful. Dr. Dubin concluded that Triallate did not produce a carcinogenic effect in this study.

V. Summary

A statistically significant increase in tumor incidence has been demonstrated for Avadex (Diallate) but not for Avadex BW (Triallate). Diallate was tested in several studies on rats and mice, whereas only one rat study was performed with Triallate.

In the Innes study of mice fed Diallate, there were significantly elevated incidences of hepatomas in male mice of 2 strains (X and Y) when compared with either their respective matched (vehicle) control group ($p = 1.6 \times 10^{-6}$ and $p = 1.4 \times 10^{-3}$, respectively), negative (without vehicle) control group ($p = 1.2 \times 10^{-5}$ and $p = .018$, respectively), or pooled negative control groups ($p = 2.0 \times 10^{-8}$ and $p = 2.3 \times 10^{-6}$, respectively). There was a statistically significant incidence of hepatomas in female mice of strain X when compared with the pooled control group only ($p = .023$), whereas strain Y females did not exhibit an increase of hepatomas. A statistically significant increase of pulmonary adenomas occurred in Diallate -treated males of strain X compared with the pooled controls ($p = .041$), while the incidence compared with the matched control group ($p = .051$) was only marginally significant. There was a statistically significant incidence of total tumors in the treated males of both strains X and Y ($p = 2.5 \times 10^{-7}$ and $p = 2.9 \times 10^{-3}$, respectively) and in the treated females of strain X

($p = .021$) when compared to the appropriate matched control group.

In the Boots study of female mice given Diallate intraperitoneally, there was no statistically significant increase of tumors in individual organ sites.

In the Litton Bionetics rat study, there was a statistically significant increase in total malignant tumors in the male rats of the high dose group (300 ppm) when compared with the pooled control group ($p = .032$), and with one of the two matched control groups ($p = .023$). There was no increased incidence of tumors at any specific anatomical site. Female rats of the high dose group had a statistically significant increase of carcinomas compared with the pooled controls ($p \leq .042$) but not compared with either matched control group. There was no statistically significant increase in total tumors (carcinomas and sarcomas) in the treated female rats at either dose level when compared with pooled or matched controls, nor any significant increase in specific tumor types when analyzed according to anatomical site.

The Industrial Bio-Test Rat Study of Diallate showed an increased incidence ($p = .021$) of benign mammary gland tumors in females treated with 100 ppm compared with controls. With the exception of the benign mammary tumors, there was no statistically significant increase in tumors of any other anatomical site or in total tumors in the treated

females. There was no statistically significant increase in total tumors (benign and malignant) nor in tumors of any anatomical site in treated male rats compared with controls.

The only available data for Triallate is from one rat study performed by Industrial Bio-Test. The results did not indicate a significant increase in tumor incidence in either treated males or females relative to respective controls.

VI. QUANTITATIVE RISK ASSESSMENT

A. Introduction & Summary

The following is the quantitative portion of the potential cancer risk associated with diallate use in the United States. Diallate is used on the following foods: barley, lentils, peas, safflower, soybeans, sugar cane and beet, corn (grain), and flax (seed). Risk estimates are calculated for the United States population exposed to diallate in the diet. Also, risk estimates are given for workers involved in the spray application of diallate.

It was found that for conservative but not unreasonable estimated levels of exposure that the lifetime cancer risk for all food is 1.5×10^{-6} which would result in about 5 cases per year in the total U.S. population. However, applicators who were unprotected experienced a dermal risk under conservative exposure assumptions as high as 9.6×10^{-4} . This risk fortunately is reduceable to as low as 1.2×10^{-5} with proper protective clothing. Since the number of applicators are fairly limited the expected cancer cases in the entire cohort for their lifetime would be less than one.

B. Bioassay Data Utilized

The evidence for a carcinogenic effect of diallate involves four independent animal bioassay studies on rats and mice. The results of these studies are presented in the qualitative portion of the risk assessment.

The animal bioassay data utilized for the quantitative risk assessment were based on the Innes oral feeding study on mice. For this study the one treated group of mice were fed 560 ppm of diallate in the diet. A statistically significant higher incidence of hepatomas in males of both strains X and Y was observed, when compared to matched controls.

The proportion of hepatomas observed in Strain X males was used to calculate the slope parameter for the one-hit model, adjusting for background tumor incidence. Table 1 presents the data for the Strain X males. Therefore, using the proportion of hepatomas in the matched control group and the treated group, the one-hit slope parameter is:

$$B = - \ln [(1 - 13/16)/(1 - 0/16)] / 560 = 2.989 \times 10^{-3}$$

The estimated lifetime probability of a Dimilin caused cancer death (P) is

$$P = BX = (2.989 \times 10^{-3})X$$

where X is the average equivalent exposure of Dimilin (ppm) in the diet.

C. Lifetime Probability of Diallylate-caused Cancer Cases

1. Dietary Exposure

The human population receives direct dietary exposure to diallylate residues through consumption of specific foods. These foods are: barley, lentils, peas, safflower, soybeans, sugar cane and beet, corn (grain), and flax (seed).

Maximum or "worst case" exposure was developed from tolerances established for residues of diallylate in foods. It is assumed that residues are present in individual foods to the extent permitted by the tolerances and that the foods are uniformly distributed throughout the country. Table 2 presents the cancer risk to the entire U. S. population from "worst case" dietary exposure to diallylate.

A second set of estimates were developed utilizing information on the percentage of crop treated made available by BFSB (Reference: Charles R. Lewis, "Diallylate Data for Exposure Analysis", 9-12-78). Table 3 presents the cancer risk estimates when the percentage crop treated is considered. Since no information was available for safflower, it was assumed that 100% of the crop was treated.

2. Spray Applicator Exposure

Exposure information for the applicators was obtained from the Environmental Fate Branch (HED). Diallylate is applied primarily as an emulsified concentrate with ground equipment by boom sprayer. Therefore, spray applicators are exposed to diallylate by inhalation of the volatilization compound and by dermal exposure during the loading of the sprayer or in the application process. Applicator's exposure to diallylate from granular applications is very low and was not considered in the exposure analysis.

Since exposure estimates for diallylate have never been measured, exposure information is based on worker exposure to triallylate. It is assumed that the two compounds are similar in use pattern and in rate of application. The estimates based on triallylate were verified using a model for paraquat which calculates the amount of pesticide liquid formulation that comes in contact with the applicator's skin.

The estimated dosages were reported in mg/hr. and then converted to mg/kg/year. The conversion from mg/kg/year to equivalent lifetime ppm in the diet is as follows,

$$X = \frac{(60u) \times 40 \text{ years}}{365 \frac{\text{days}}{\text{year}} \times 70 \text{ years} \times 1.5 \text{ kg}} = 6.26 \times 10^{-2} u = \frac{\text{mg per lifetime diallylate}}{\text{kg food eaten per lifetime}}$$

where X is ppm in diet and u is mg/kg/yr of exposure. A 40-year working history and a 70-year lifetime is assumed for the applicators.

Table 4 presents data on the absorbed dose in mg/kg/yr., the lifetime average dose in the diet (ppm), the lifetime probability of a cancer due to diallate and the expected cancer cases/year due to diallate for spray applicators.

TABLE 1

Innes Study

Strain X

Male Mice

Proportion of Male Mice with Liver Tumors
By Exposure Group

Exposure Group (ppm)	Proportion with Liver Tumors
Control (Matched) 560	0/16
	13/16

¹ $p \leq 1.61 \times 10^{-6}$

TABLE 2
 CANCER RISK TO U.S. POPULATION FROM
 EXPOSURE TO DIALLATE BASED ON TOLERANCE LEVELS

Source	mg/kg (ppm)	Lifetime Probability of Cancer Due to Diallylate	Expected Number of Diallylate Caused Cancer Cases Per Year
Barley	.000013	3.885×10^{-8}	< 1
Lentils	.00002	5.978×10^{-8}	< 1
Peas	.00035	1.046×10^{-6}	3
Potatoes	.00271	8.100×10^{-6}	25
Safflower	.000013	3.885×10^{-8}	< 1
Soybeans	.00046	1.375×10^{-6}	4
Sugar cane & beet	.00182	5.440×10^{-6}	17
Corn, grain	.0005	1.495×10^{-6}	5
Flax, seed	.000013	3.885×10^{-8}	< 1
Total	.005899	1.763×10^{-5}	55

TABLE 3

CANCER RISK TO U.S. POPULATION FROM DIETARY EXPOSURE
TO DIALLATE BASED ON TOLERANCE LEVELS AND PERCENT CROP TREATED

Source	mg/kg (ppm) considering percent crop treated	Percent of Crop Treated with Diallate	Lifetime Probability of Cancer due to Diallate	Expected number of Diallate Caused Cancer Cases Per Year
Barley	.000000	.10	-----	-----
Lentils	.000067	38	2.003 x 10 ⁻⁷	1
Peas	.000033	10	9.864 x 10 ⁻⁸	< 1
Potatoes	.000013	.46	3.886 x 10 ⁻⁸	< 1
Safflower	.000013	100	3.886 x 10 ⁻⁸	< 1
Soybeans	.000000	.20	-----	-----
Sugar, cane & Reet	.000387	21.3	1.157 x 10 ⁻⁶	4
Corn, grain	.000000	.009	-----	-----
Flax, seed	.000000	3	-----	-----
Total	.000453		1.534 x 10 ⁻⁶	5

TABLE 4

LIFETIME CANCER RISK TO SPRAY
APPLICATORS EXPOSED TO DIALLATE

Population (2380)	Estimated Dose mg/hr	Duration of Exposure	Dose in mg/kg/yr	Dose in ppm	Lifetime Probability of Cancer due to Diallate	Expected number of Diallate Caused Cancer Cases per Year
<u>DERMAL</u>						
Absence of protective clothing	25.8	6-12 hr/yr	2.58 5.16	.1615 .3230	4.827 x 10 ⁻⁴ 9.654 x 10 ⁻⁴	1.641 x 10 ⁻² 3.280 x 10 ⁻²
Absence of protective clothing (Assuming 10% dermal absorption)	2.58	6-12 hr/yr.	.258 .516	.0162 .0323	4.827x10 ⁻⁵ 9.54x10 ⁻⁵	1.641 x 10 ⁻³ 3.280 x 10 ⁻³
With protective clothing	6.5	6-12 hr/yr.	.65 1.3	4.069 x 10 ⁻² 8.138 x 10 ⁻²	1.216 x 10 ⁻⁴ 2.432 x 10 ⁻⁴	4.134 x 10 ⁻³ 8.271 x 10 ⁻³
With protective clothing (Assuming 10% protective clothing)	.65	6-12 hr/yr.	.065 .13	4.069x10 ⁻³ 8.138x10 ⁻³	1.216 x 10 ⁻⁵ 2.432 x 10 ⁻⁵	4.134 x 10 ⁻⁴ 8.271 x 10 ⁻⁴
<u>INHALATION</u>						
Without mask	.09	6-12 hr/yr.	.009 .018	5.643 x 10 ⁻⁴ 1.127 x 10 ⁻³	1.684 x 10 ⁻⁶ 3.369 x 10 ⁻⁶	5.726 x 10 ⁻⁵ 1.145 x 10 ⁻⁴
With Mask (10% of Exposure w/o mask)	.09	6-12 hr/yr.	.0009 .0018	5.634 x 10 ⁻⁵ 1.127 x 10 ⁻⁴	1.684 x 10 ⁻⁷ 3.369 x 10 ⁻⁷	5.726 x 10 ⁻⁶ 1.145 x 10 ⁻⁶

Report On Histopathologic Studies of
Monsanto Triallate (Avadex-BW)
Experiment On Charles River Albino CD Rats

I. N. Dubin, M. D.

The study, a 2-year chronic oral toxicity study, was done in 1976-1977 by Industrial Bio-Test Laboratories, Northbrook, Illinois, 60062. The pathologic studies were carried out for the latter company by Dr. Donovan Gordon, Veterinary Pathologist.

I studied all available slides on male and female control animals (Experiment B5250); also, on all male and female animals in group T-II (100 ppm), experiment B5251; with the exception of a small number of control and test animals in which slides were missing. The numbers of animals I examined are recorded in a list I have sent you previously.

I have also sent you previously a detailed breakdown of all tumors in control and test animals broken down by origin of tumor, sex, control group, test group, and whether the animals lived to reach the 2-year endpoint or died or were sacrificed before this endpoint. I also sent you detailed histopathologic diagnoses on each animal, case by case.

My conclusions are as follows:

1. Slides were missing in only 7 animals. I examined slides from 59 control animals and 60 test animals.
 2. I agreed with all the diagnoses made by Dr. D. Gordon, except that he missed one small hepatocellular carcinoma in one animal, (No. 223). Since liver tumors were rare, this is not significant.
- 495

3. There is one flaw in the experimental design, namely, that when animals died, or were killed on the point of dying, prior to the planned termination of the experiment at the end of 2 years, there was no routine sectioning of all tissues for histological examination; only tissues which were suggestive of presence of tumor were sampled for histologic study. Thus, this could have introduced an element of bias.

Unfortunately, this bad practice is followed by many laboratories performing experiments for carcinogen bioassay.

4. The only significant increase in tumors occurring in the Triallate-treated animals was in the female rats surviving 2 years. In the female control rats surviving 2 years, 9 of 22 animals showed a pituitary chromophobe adenoma; in the Triallate-treated (100 ppm) female rats, 13 of 15 animals showed a similar pituitary tumor. The statistical analysis by Dr. Todd Thorslund indicates this difference to be significant at $p < .01$ level.

While this difference is statistically significant, I am inclined to believe it is not biologically meaningful.

In the experience of the NCI pooled data, the untreated Charles River CD Albino rat demonstrates a high incidence of spontaneous pituitary adenomas about 34% in the males and 58% in the females. Please see the table appended to the DBCP paper by Marie McKeon and Gordon Edwards, presented at the last Carcinogen Assessment Group on September 2, 1977; the table is entitled "Percent Spontaneous Primary Tumors in Untreated Species used at the NCI for Carcinogen Bioassay." 141

Thus, I found no carcinogenic effect produced by Triallate (Avadex-BW) on Charles River CD rats at 100 ppm, the level at which most tumors were found.

Sincerely yours,

I. N. Dubin

I. N. Dubin, M. D.
Professor and Former Chairman
Department of Pathology

11/19
H

Triallan

THE MEDICAL COLLEGE OF PENNSYLVANIA AND HOSPITAL

3300 HENRY AVENUE • PHILADELPHIA, PA. 19129
215-842-6000

August 15, 1977

Dr. Elizabeth Anderson
Carcinogen Assessment Group
Environmental Protection Agency
401 "M" Street S.W. (RD-672)
Washington, D. C. 20460

Dear Dr. Anderson:

I am enclosing a copy of the following items:

- 1 - Histological description of all the slides I examined on the animals in the TRIALLATE (AVADEX - BW) study.
- 2 - I also have listed on a separate page those animals in which slides were missing.
- 3 - I am enclosing a set of four tables indicating the tumors I found in the animals, broken up by Control and Test animals, male and female animals, and whether the animals lived out the two year span or died before the end of the experiment.

When Dr. Thorslund informs you as to whether or not there are any significant differences between the Test and Control animals, please notify me accordingly. You will recall I was to withhold my final summary report until I had that information.

Sincerely yours,

Nathan Dubin

I. N. Dubin, M. D.

1977

TUMORS FOUND IN TRIALLATE ANIMALS, CONTROL MALES

<u>Tumor</u>	<u>Sacrificed at 2 years</u> <u>16 animals</u>	<u>Found dead or moribund sacrifice</u> <u>6 animals</u>
Liver, tiny benign nodules	4	1
Liver, sarcoma	0	1
Pituitary, chromophobe adenomas	6	0
Thyroid, adenoma	1	0
parathyroid, adenoma	1	0
pancreas, benign islet cell tumor	1	0
pancreas, malignant islet cell tumor	1	0
Adrenal, cortical adenoma	1	0
Reticulum cell sarcoma	2	1
Skin, malignant tumors	0	2
Lung, metastatic tumor	0	1

TUMORS IN TRIALLATE ANIMALS, CONTROL FEMALES

<u>Tumor</u>	<u>Sacrificed at 2 years</u> <u>22 animals</u>	<u>Found dead or moribund sacrifice</u> <u>15 animals</u>
Liver, small neoplastic nodule, benign	1	0
pituitary, chromophobe adenomas	9	3
Adrenal, cortical adenoma	2	0
Skin, squamous cell carcinoma	1	0
Skin, sarcoma	1	1
Breast, benign fibroadenoma	4	5
Breast, carcinoma	4	4
Uterus, carcinoma	1	1
OVARY, granulosa cell tumor	1	0

TUMORS IN TRIALLATE ANIMALS, MALES, 100 ppm

<u>Tumor</u>	<u>Sacrificed at 2 years</u> <u>15 animals</u>	<u>Found dead or moribund sacrifice</u> <u>9 animals</u>
Pituitary, chromophobe adenoma	7	2
parathyroid, adenoma	2	0
Liver, benign neoplastic nodule	2	0
Liver, hepatocellular carcinoma	1	0
Lung, adenoma	1	0
Spleen, hemangioma	1	0
Pancreas, islet cell adenoma	2	0
Thyroid, adenoma	3	0
Skin, sarcoma	0	1
Reticulum cell sarcoma	0	1
Breast, benign fibroadenoma	1	0

TUMORS IN TRIALLATE ANIMALS, FEMALES, 100 PPM

<u>Tumor</u>	<u>Sacrificed at 2 years</u> <u>15 animals</u>	<u>Found dead or moribund sacrifice</u> <u>21 animals</u>
Pituitary, chromophobe adenomas	13	7
Breast, benign	4	6
Breast, carcinoma	1	9
Parathyroid, adenoma	1	0
Adrenal, cortical adenoma	1	0
Thymoma	1	0
Uterus, carcinoma	1	0
Thyroid, adenoma	1	0
Pancreas, islet cell adenoma	1	0
Pancreas, acinar carcinoma	1	0
Liver, neoplastic nodule	1	0
Skin, fibrosarcoma	0	2
Reticulum cell sarcoma	0	1

MONSANTO - TRIALLATE (AVADEX - BW)

SLIDES MISSING:

- (a) "Added controls" animal No. 34, male.
Nos. 67, 72, 86, female
- (b) Female control No. 98; died or moribund sacrifice.
" " - I didn't find No. 77, but found No. 76
- (c) T-II (100 ppm) Male, No. 250
" " Female, No. 272, died or moribund sacrifice
-

Numbers of animals I examined histologically:

(A) CONTROLS EXPERIMENT B5250:

(a) Sacrificed at end of experiment (2 years)

Males - 16 animals
Females - 22 animals

(b) Found dead or moribund sacrifice. (Not all tissues examined; tissues selected if suggestion of "tumor" on gross examination).

Males - 6 animals
Females - 15 animals

(B) T-II (100 ppm) EXPERIMENT B5251:

(a) Sacrificed at end of experiment (2 years)

Males - 15 animals
Females - 15 animals

(b) Found dead or moribund sacrifice.

Males - 9 animals
Females - 21 animals

1503 15 1
D 10

Monsanto TRIALLATE (AVADEX-B.W.)

"2-year chronic oral toxicity study in Charles River albino rats"

Study done 1976-1977 by Industrial Bio-Test Laboratories, 1810 Frontage Road, Northbrook, Illinois, 60062.

Pathology studies done by Dr. Donovan Gordon, Veterinary Pathologist at Industrial Bio-Test Laboratories.

The following are histopathologic diagnoses on all tissues on all animals in which tissue sections were made available to I. N. Dubin, M. D.; diagnoses were made in individual animals, case by case.

GROUP A

Experiment No. B5250, male controls, sacrificed at end of experiment (2 years).

Animal #7 Liver - slight focal necrosis and round cell infiltration; focal vacuolization. Heart - focal inflammation. Kidneys - severe chronic nephritis. Respiratory - mild inflammation of trachea and lungs. Pituitary - chromophobe adenoma. Thyroid - adenomas. Parathyroid - hyperplasia or adenoma. Adrenals - hemorrhagic area, focal calcification and vacuolization of cortex. Prostate - concretions. Normal - spleen, eyes, esophagus, stomach, small and large intestine, pancreas, bonemarrow, lymph-node, testis, urinary bladder, epididymis, diaphragm, salivary glands.

Animal #8 Liver - suggestion of an area of early nodule formation, benign hyperplasia. Kidney - moderate nephritis, chronic. Respiratory - chronic inflammation of trachea and bronchi. Normal - bonemarrow, CNS (central nervous system), eyes, spleen, heart, striated muscle, lymph-nodes, testis, epididymis, prostate, bladder, salivary glands, pituitary, trachea, thyroid, parathyroid, adrenal, stomach, esophagus, pancreas, small and large intestine.

Animal #10 Thyroid - slight hyperplasia. Liver - slight round cells, slight vacuolization, some centrolobular cytomegaly. Kidneys - slight chronic inflammation. Heart - focal myocarditis. Lung - chronic bronchitis and focal pneumonia. Normal - CNS, eyes, bonemarrow, pituitary, adrenals, parathyroid, esophagus, stomach, small and large intestine, pancreas, striated muscle, lymph-nodes, testis, epididymis, prostate, bladder.

Animal #13 Adrenal - cortical hemorrhages; one medulla hyperplastic. Pituitary - chromophobe adenoma. Thyroid - slight hyperplasia. Trachea - chronic inflammation. Lungs - chronic bronchitis. Heart - slight myocarditis. Kidneys - moderate nephritis. Normal - eyes, CNS, bonemarrow, liver, spleen, striated muscle, prostate, testis, bladder, epididymis, esophagus, stomach, pancreas, small and large intestine, salivary glands, lymph nodes.

Animal #14 Testes - bilateral tubular degeneration and some interstitial cell hyperplasia. Heart - slight focal inflammation. Liver - one nodule (hyperplastic or neoplastic); congestion. Kidney - moderate inflammation. Lung - chronic bronchitis and focal pneumonia. Pituitary - chromophobe adenoma. Normal - bonemarrow, striated muscle, bladder, prostate, epididymis, spleen, CNS, eyes, adrenal, thyroid, lymph-nodes, stomach, pancreas, large and small intestine, salivary glands.

Animal #16 Lung - chronic bronchitis. Kidney - slight chronic inflammation. Heart - slight myocarditis. Pancreas - slight focal fibrosis. Normal - CNS, bonemarrow, eyes, lacrimal glands, liver, testis, epididymis, bladder, prostate, lymph-nodes, salivary glands, striated muscle, esophagus, stomach, large and small intestine, trachea, thyroid, parathyroid, pituitary, adrenal. (No spleen seen.)

Animal #17 Pituitary - chromophobe adenoma. Heart and lungs - slight chronic inflammation. Kidneys - chronic nephritis. Trachea - inflamed. Liver - focal congestion; ? small beginning nodule. Normal - CNS, bonemarrow, eyes, spleen, testis, bladder, epididymis, prostate, striated muscle, esophagus, stomach, large and small intestine, pancreas, salivary gland, adrenal, lymph-nodes, thyroid, parathyroid.

Animal #24 Heart - slight inflammation. Kidneys - severe nephritis. Lungs - chronic bronchitis and focal pneumonia. Trachea - slight inflammation. Pituitary - either vascular epithelial hyperplasia or adenoma. Prostate - concretions. Salivary glands - chronic inflammation of parotid; other salivary glands OK. Pancreas - invasive carcinoma, probably from islets of Langerhans. Normal - CNS, eyes, spleen, liver, esophagus, stomach, small and large intestine, adrenals, thyroid, parathyroid, testis, bladder, epididymis, vas deferens, seminal vesicles, striated muscle.

Animal #26 Adrenal - one cortical adenoma. Heart - slight myocarditis. Kidney - mild nephritis. Liver - slight inflammation and fibrosis of portal areas; one cyst. Lungs - chronic bronchitis, focal pneumonia, focal aggregates of alveolar macrophages. Pancreas - islet cell adenoma. Normal - CNS, bonemarrow, eyes, lacrimal glands, trachea, thyroid, parathyroid, spleen, bladder, testis, epididymis, prostate, striated muscle, esophagus, stomach, small and large intestine, salivary glands, lymph-nodes.

Animal #30 Heart - slight inflammation. Kidneys - moderate nephritis. Liver - one hemorrhage. Lungs - chronic bronchitis and focal pneumonia. Epididymis - focal inflammation. Trachea - inflamed. Normal - CNS, bonemarrow, eyes, spleen, bladder, testis, prostate, seminal vesicles, thyroid, parathyroid, adrenal, esophagus, stomach, large and small intestine, pancreas, lymph-nodes, salivary glands.

Animal #31 Kidney - severe nephritis. Heart - Minimal inflammation. Lung - abscesses and hyperplastic bronchial epithelium. Normal - bonemarrow, CNS, eyes, striated muscle, bladder, adrenal, pituitary, testis, epididymis, prostate, pancreas, salivary glands, esophagus, stomach, large and small intestine, lymph nodes, spleen, liver. (No thyroid or parathyroid.)

Animal #32 Pituitary - small adenoma. Tracheitis. Adrenals - one shows cortical vacuolization. One of testes - tubular degeneration. Lungs - chronic bronchitis, focal pneumonia, focal alveolar macrophages. Heart and kidneys - slight inflammation. Liver - possible early tiny hyperplastic nodule. Normal - eyes, salivary glands, CNS, bonemarrow, thyroid, bladder, prostate, epididymis, spleen, striated muscle, esophagus, stomach, large and small intestine. (No pancreas or parathyroid.)

Animal #35 Tracheitis. Kidneys - minimal inflammation. Lungs - severe bronchitis, focal pneumonia, focal alveolar macrophages. Normal - CNS, eyes, bonemarrow, pituitary, esophagus, stomach, large and small intestine, pancreas, thyroid, adrenals, bladder, striated muscle, testis, epididymis, prostate, pancreas, lymph nodes, heart, spleen, liver.

Animal #39 Severe tracheitis. Lungs - severe bronchitis, chronic pneumonia, pulmonary fibrosis, and severe hyperplasia of bronchial epithelium. Heart - slight inflammation. Kidney - severe inflammation. Spleen - sarcoma, either hemangiosarcoma or vascular reticular sarcoma. Normal - eyes, bonemarrow, CNS, thyroid, parathyroid, pituitary, adrenal, striated muscle, bladder, testis, epididymis, prostate, liver, esophagus, stomach, small and large intestine, salivary glands, lymph nodes. (No pancreas.)

Animal #46 Heart - slight inflammation. Kidneys - moderate nephritis. Lungs - severe bronchitis and focal pneumonia. Thyroid - slight hyperplasia. Slight tracheitis. Normal - liver, spleen, eyes, CNS, bonemarrow, striated muscle, testis, bladder, prostate, vas, seminal vesicles, adrenal, pituitary, parathyroid, esophagus, stomach, small and large intestine, pancreas, salivary glands, lymph nodes.

Animal #49 Heart - slight inflammation. Kidneys - moderate nephritis. Lungs - severe bronchitis with epithelial hyperplasia, pulmonary fibrosis and focal pneumonia. Slight tracheitis. Normal - eyes, bonemarrow, CNS, muscle, bladder, epididymis, pancreas, large and small intestine, adrenals, thyroid, parathyroid, pituitary, esophagus, stomach, salivary glands, lymph nodes.

GROUP B

Experiment No. B5250, control females, sacrificed at end of experiment (2 years).

Animal #51 Adrenals - cortical hemorrhages in both. Liver - few portal round cells. Kidneys - slight inflammation. Lungs - severe bronchitis and focal pneumonia. Lymph nodes - hyperplastic. Ovaries - corpora lutea, normal. Large intestine - parasites in lumen. Normal - bonemarrow, eyes, CNS, thyroid, parathyroid, pituitary, spleen, heart, pancreas, salivary glands, uterus, bladder, striated muscle, esophagus, stomach, small bowel.

Animal #52 Kidneys - slight inflammation. Lungs - severe bronchitis and focal severe pneumonia. Adrenals - severe hemorrhages and cysts.

in cortex. Uterus - inflamed. Normal - eyes, heart, CNS, bone-marrow, liver, spleen, thyroid, parathyroid, pituitary, pancreas, lymph nodes, salivary glands, muscle, esophagus, stomach, large and small bowel, ovaries, bladder.

Animal #55 Kidneys - slight inflammation. Liver - focal round cells in parenchyma and triads. Lungs - chronic bronchitis and regional pneumonia with fibrosis. Slight tracheitis. Adrenals - cortical hemorrhages and cysts. Lymph nodes - hyperplastic. Uterus - suppurative endometritis. Normal - heart, spleen, eyes, CNS, bone-marrow, thyroid, parathyroid, pituitary, pancreas, salivary glands, muscle, esophagus, stomach, large and small bowel, bladder.

Animal #64 Skin - Squamous cell carcinoma. Uterus - inflamed. Trachea - severe inflammation. Adrenals - cortical hemorrhages in one. Heart and Kidneys - slight inflammation. Lungs - severe bronchitis and focal pneumonia. Normal - eyes, CNS, salivary glands, pancreas, lymph nodes, muscle, esophagus, stomach, small and large bowel, bladder, ovaries, pituitary, thyroid, parathyroid, spleen, liver.

Animal #66 Lungs - bronchitis, pneumonia, alveolar macrophages and in one section, abscess and fibrosis. Kidneys - slight inflammation. Liver - focal round cells. Uterus - inflammation, abscess, hemorrhage. Adrenals - cortical hemorrhages and cysts. Colon - parasites in lumen. Normal - heart, spleen, CNS, eyes, bonemarrow, muscle, bladder, lymph nodes, salivary glands, ovaries, thyroid, pituitary, esophagus, stomach, pancreas, small intestine.

Animal #68 Severe tracheitis. Adrenals - cortical hemorrhages and cysts. Pituitary - focal hyperplasias and adenomas. Kidneys - slight inflammation. Liver - one section, suggestion of hyperplastic nodule. Lungs - huge abscesses. Uterus - purulent endometritis. A large unidentified secretory glandular tumor - could be breast. Normal - bonemarrow, eyes, CNS, thyroid, heart, spleen, muscle, bladder, esophagus, stomach, large and small bowel, pancreas, salivary glands. Ovary - cyst.

Animal #69 Pituitary - chromophobe adenoma. Kidneys and Lung - slight inflammation. Liver - minimal round cells in triads. Severe tracheitis. Adrenals - cortical cysts and hemorrhages. Normal - CNS, eyes, bonemarrow, heart, spleen, thyroid, parathyroid, esophagus, stomach, large and small bowel, pancreas, muscle, lymph nodes, salivary glands, bladder, uterus, ovaries.

Animal #73 Severe tracheitis. Lung - severe bronchitis with epithelial hyperplasia and lung abscess. Adrenals - cortical hemorrhages and cysts. Colon - parasites in lumen. Heart - slight inflammation. Uterus - endometritis. Ovaries - cysts. Pituitary - adenomas. Spleen - a local mass of pale-cells, reticular type (? early reticular sarcoma). A large unidentified adenocarcinoma, probably breast. Normal - thyroid, parathyroid, eyes, CNS, bone-marrow, salivary glands, lymph nodes, pancreas, esophagus, stomach, small intestine, kidney, liver, muscle, bladder.

Animal #75 Lacrimal gland - inflamed. Pituitary - chromophobe Adenoma. Adrenals - cortex shows vacuolization, hemorrhage, cysts, adenomas. Severe tracheitis. Lungs - marked bronchitis with focal pneumonia. Kidneys - focal calcification. Normal - CNS, eyes, bonemarrow, lymph nodes, thyroid, parathyroid, esophagus, stomach, large and small bowel, pancreas, salivary glands, spleen, liver, heart, muscle, bladder, uterus, ovaries.

Animal #76 Pituitary - adenoma. Heart - slight inflammation. Lung - bronchitis and focal pneumonia. Adrenals - cortical hemorrhage and cysts in one; cortical adenoma in other. Moderate tracheitis. Uterus - endometritis. Normal - eyes, CNS, bonemarrow, spleen, liver, kidneys, thyroid, esophagus, stomach, large and small bowel, pancreas, muscle, bladder, ovaries, lymph nodes, salivary glands.

Animal #82 Adrenals - cortical hemorrhages, cysts and vacuolization. Heart and Kidneys - minimal inflammation. Lungs - chronic bronchitis. Uterus - purulent endometritis. Normal - pituitary, CNS, parathyroid, thyroid, liver, spleen, eyes, esophagus, stomach, large and small bowel, pancreas, salivary glands, lymph nodes, muscle, bladder, ovaries.

Animal #84 Severe tracheitis. Lungs - marked bronchitis and focal pneumonia. Adrenals - cortical hemorrhage. Pituitary - focal adenomas. Normal - bonemarrow, thyroid, eyes, heart, CNS, muscle, uterus, bladder, liver, spleen, kidney, heart, lymph nodes, salivary glands, pancreas, esophagus, stomach, large and small bowel.

Animal #87 Kidney - focal inflammation and calcification. Lung - chronic bronchitis and focal pneumonia. Adrenal - one shows cortical hemorrhages and cysts. Uterus - slight endometritis. Breast-adenocarcinoma. Normal - bonemarrow, CNS, heart, spleen, liver, thyroid parathyroid, pituitary, muscle, cervix, bladder, ovaries, esophagus, stomach, large and small bowel, pancreas, salivary glands, lymph nodes.

Animal #88 Pituitary - large adenoma. Spleen - marked hematopoiesis. Lung - chronic bronchitis. Uterus - slight inflammation. Tracheitis. Adrenals - cortical hemorrhages and some giant cells. A large necrotic cystic mass, apparently of glandular origin, probably breast; could be galactoceles or necrotic breast tumor. Normal - eyes, bonemarrow, CNS, kidney, liver, muscle, heart, bladder, thyroid, parathyroid, esophagus, stomach, large and small bowel, lymph nodes, pancreas, salivary glands.

Animal #90 Heart - focal inflammation and fibrosis. Pituitary - cyst. Spleen - marked hematopoiesis. Liver - few portal round cells and slight hematopoiesis. Kidney - slight inflammation. Lung - chronic bronchitis and focal pneumonia. Breast - benign fibroadenoma. Uterus and Cervix - some inflammation. Tracheitis. Adrenals - cortical hemorrhages and vacuolization. Normal - eyes, CNS, bonemarrow, lymph nodes, salivary glands, pancreas, muscle, ovaries, bladder, esophagus, stomach, large and small bowel, thyroid, parathyroid.

Animal #92 Heart and Kidney - minimal inflammation. Lung - focal chronic pneumonia. Adrenal - one has cortical hemorrhages. Uterus - slight inflammation. Ovary - granulosa cell proliferation. Normal - eyes, bonemarrow, CNS, pituitary, spleen, liver, thyroid, esophagus, stomach, large and small bowel, muscle, bladder, cervix, pancreas, salivary glands, lymph nodes.

Animal #93 Uterus - inflammation. Pituitary - slight hyperplasia. Heart and Kidneys - focal inflammation. Spleen - hematopoiesis. Liver - few portal round cells. Lungs - chronic pneumonia. Adrenals - congestion. Parathyroid - adenoma. Normal - bonemarrow, eyes, CNS, salivary glands, pancreas, lymph nodes, muscle, thyroid, esophagus, stomach, large and small bowel.

Animal #94 Colon - parasite. Adrenals - cortical cysts and hemorrhages. Severe bronchitis. Lungs - chronic bronchitis, focal pneumonia and alveolar macrophages. Invasive adenocarcinoma with suppuration - could be primary breast or endometrium. Liver - slight portal round cells. Kidneys - focal calcification. Breast - papillary adenocarcinoma. Normal - bonemarrow, eyes, pituitary, CNS, esophagus, stomach, small bowel, thyroid, lymph nodes, pancreas, salivary glands, bladder, ovaries, spleen. Parathyroid - hyperplasia. One section of uterus - normal.

Animal #95 Adrenal - massive cyst with fibrosis. Heart - slight inflammation. Tumor mass, papillary with fibrosis - probably breast. Severe bronchitis. Lungs - chronic bronchitis and focal pneumonia. Normal - eyes, bonemarrow, CNS, esophagus, stomach, large and small bowel, thyroid, pituitary, liver, spleen, kidneys, pancreas, salivary glands, lymph nodes, muscle, bladder, uterus, ovaries.

Animal #96 Liver - slight focal vacuolization, cytoplasmic. Pituitary - adenoma. Lung - severe bronchitis and moderate pneumonia. Thyroid - slight hyperplasia. Adrenals - one large cortical adenoma. Cervix - slight inflammation. Large sarcoma - apparently in skin. Normal - CNS, eyes, bonemarrow, kidney, spleen, muscle, bladder, ovaries, uterus, heart, salivary glands, pancreas, lymph nodes, esophagus, stomach, large and small bowel.

Animal #99 Heart and Kidney - slight inflammation. Spleen - hematopoiesis. Lung - chronic bronchitis: small adenocarcinoma with pleural involvement. Breast - fibroadenoma. Uterus - adenocarcinoma with suppuration. Normal - bonemarrow, eyes, CNS, muscle, ovary, liver, thyroid, parathyroid, adrenals, salivary glands, pancreas, lymph nodes.

Animal #100 Heart and Kidneys - slight inflammation. Lungs - chronic bronchitis, focal pneumonia and alveolar macrophages. Adrenals - cortical hemorrhages and cysts. Thyroid - slight hyperplasia. Pituitary - hyperplasia. Breast - large fibroadenoma. Endometritis. Cystic structure with secretions and calcification - salivary gland retention. Normal - CNS, eyes, bonemarrow, liver, spleen, parathyroid, pancreas, lymph nodes, esophagus, stomach, large and small bowel, ovaries, muscle, bladder.

- / -

GROUP C

Control males.

Experiment No. B5250, Died or moribund sacrifice. Tissues selected for histologic study.

Animal #5 Found dead. Reticulum cell sarcoma with giant cells - in stomach, liver, lung and adipose tissue. Heart and Kidney - minimal inflammation. Skin - fibroma durum. Testis and epididymis - normal.

Animal #12 Found dead. Liver - 2 small benign hyperplastic nodules. Kidney and Lung - slight inflammation. Skin - fibrosarcoma. Normal - stomach, heart, spleen, testis, epididymis.

Animal #37 Found dead. Two sarcomas - one, compatible with neuro-fibrosarcoma; the other, with sarcoma. Lung - chronic bronchitis and focal pneumonia. Liver - infarcts; one multilocular cyst, could be a hemangioma. Normal - spleen, heart, kidney, testis, epididymis.

Animal #41 Found dead. Liver - sarcoma with many Langhans type giant cells. Spleen - normal.

Animal #50 Lung - foci suggestive of metastatic tumor; also, severe acute pneumonia.

Animal #70 Lymph node - lymphogenous cyst.

GROUP D

Experiment No. B5250, control females. Died or moribund sacrifice. Selected tissues.

Animal #53 Found dead. Breast-fibroadenoma. Adrenals - cortical cysts and hemorrhages.

Animal #54 Found dead. Breast-adenocarcinoma. Bonemarrow - normal.

Animal #59 Found dead. Breast - fibroadenoma.

Animal #60 Found dead. Uterus - endometrial adenocarcinoma. Adrenals - cortical hemorrhages and cysts. Spleen - OK.

Animal #62 Large encapsulated mass with granulation tissue, fibrosis, necrosis, focal calcification - site and nature undetermined. Lung - chronic interstitial thickening. Spleen - OK.

Animal #63 Found dead. Breast - fibroadenomas. Spleen - OK.

Animal #74 Found dead. Breast - adenocarcinoma.

Animal #78 Moribund sacrifice. Pituitary - large chromophobe adenoma.

Animal #79 Moribund sacrifice. Pituitary - chromophobe adenoma.

1211

Animal #80 Found dead. Breast - benign adenoma.

Animal #81 Found dead. Breast - fibroadenoma.

Animal #83 Breast - adenocarcinoma; invading liver, pancreas, fat, perirenal fat, lung, splenic capsule, striated muscle. Normal - stomach, adrenal.

Animal #85 Found dead. Pituitary - chromophobe adenoma. Spleen - OK. Suppurative endometritis.

Animal #89 Moribund sacrifice. Skin - either sarcoma or anaplastic carcinoma.

Animal #90 Found dead. Breast - necrotic adenocarcinoma.

GROUP E

Experiment No. B-5251. Test group T-II, 100 ppm. Sacrificed males.

Animal #202 Tracheitis. Thyroid, slight hyperplasia. Testes - some tubular degeneration. Pituitary - hyperplasia. Lungs - chronic bronchitis and pneumonia. Normal - CNS, eyes, bonemarrow, skin, esophagus, pancreas, salivary glands, lymph nodes, adrenals, parathyroid, stomach, large and small bowel, muscle, bladder, epididymis, prostate, heart, kidney, spleen, liver.

Animal #204 Heart - fibrosis. Lungs - severe bronchitis and severe pneumonia. One parathyroid hyperplastic. Thyroid - slight hyperplasia. Kidneys - severe chronic inflammation. Liver - lymphatic or vascular hamartomas. Normal - skin, bonemarrow, eyes, CNS, pituitary, muscle, bladder, testis, epididymis, prostate, adrenals, lymph node, pancreas, salivary glands, esophagus, stomach, large and small bowel.

Animal #205 Tracheitis. Liver - 2 small hyperplastic nodules, one vascular, tubular; the other, vacuolated. Heart - focal inflammation. Kidneys - moderate inflammation. Lung - large adenoma; severe chronic bronchitis and pneumonia. Normal - eyes, bonemarrow, CNS, salivary glands, lymph nodes, pancreas, esophagus, stomach, large and small bowel, skin, pituitary, adrenals, thyroid, parathyroid, muscle, bladder, prostate, testis, epididymis, spleen.

Animal #208 Tracheitis. Kidney - cortical hamartoma. Liver - few portal round cells. Lungs - severe chronic bronchitis and pneumonia. Heart - slight inflammation. Normal - CNS, adrenals, pituitary, thyroid, spleen, bonemarrow, eyes, skin, esophagus, stomach, large and small bowel, muscle, bladder, testis, epididymis, prostate, pancreas, salivary glands, lymph nodes.

Animal #209 Thyroid - concretions. Severe tracheitis. Lungs - severe bronchitis and pneumonia. Heart and Kidney - focal inflammation. Liver - few portal round cells. Normal - eyes, bonemarrow, CNS, pituitary, adrenals, esophagus, stomach, large and small bowel, muscle, bladder, testis, epididymis,

prostate, spleen, skin, lymph nodes, salivary glands.

Animal #217 Pituitary - chromophobe adenoma.
Heart and Kidneys - slight inflammation. Lungs - severe bronchitis and focal pneumonia. Spleen - hemangioma and fibrosis. Liver - vascular neoplastic nodule. Adrenal - focal cortical vacuolization. Severe tracheitis. Testes - focal tubular degeneration. Normal bonemarrow, eyes, CNS, thyroid, esophagus, stomach, large and small bowel, skin, muscle, salivary glands, pancreas, lymph nodes, epididymis, prostate, seminal vesicles, vas deferens.

Animal #222 Pituitary - chromophobe adenoma.
Moderate tracheitis. Adrenals - focal cortical vacuolization. Heart and Kidneys - minimal inflammation. Lungs - severe bronchitis and focal pneumonia. Liver - few round cells. Colon - parasite. Pancreas - islet cell adenoma. Normal - eyes, bonemarrow, CNS, skin, thyroid, parathyroid, spleen, muscle, bladder, prostate, testis, epididymis, esophagus, stomach, small bowel, lymph nodes, salivary glands.

Animal #223 Severe tracheitis. Lungs - severe bronchitis and focal pneumonia. Heart - focal inflammation. Pituitary - large chromophobe adenoma. Thyroid - solid adenoma. Kidneys - moderate inflammation. Liver - moderate sized hepatocellular carcinoma with marked cellular atypia and local invasion. Normal - skin, eyes, bonemarrow, CNS, adrenals, parathyroid, testis, epididymis, muscle, bladder, prostate, spleen, esophagus, stomach, large and small bowel, pancreas, salivary glands, lymph nodes.

Animal #224 Thyroid - concretions. Parathyroid - hyperplasia. Prostate - a focus of granulomatous inflammation. Heart - focal inflammation. Kidneys - moderate inflammation. Lungs - severe bronchitis and moderate pneumonia. Liver - congestion. Normal - CNS, skin, bonemarrow, pituitary, adrenals, eyes, muscle, bladder, testis, epididymis, lymph nodes, pancreas, salivary glands, esophagus, stomach, large and small bowel.

Animal #226 Pituitary - chromophobe adenoma.
Pancreas - islet cell adenoma. Bladder - inflamed polyp. Marked tracheitis. Lungs - severe bronchitis and focal pneumonia. Heart and Kidneys - slight inflammation. Liver - moderate no. portal round cells. Normal - CNS, eyes, bonemarrow, esophagus, stomach, large and small bowel, lymph nodes, salivary glands, muscle, testis, epididymis, prostate, skin, adrenals, thyroid, parathyroid, spleen.

Animal #230 Slight tracheitis. Lungs - moderate bronchitis. Seminal vesicles - severe inflammation, with marked epithelial hyperplasia. Arteritis - of abdominal vessels. Pituitary - chromophobe adenoma. Skin - epithelial inclusion cyst. Heart and Kidneys - moderate inflammation. Liver - minimal round cell infiltration. Normal - CNS, bonemarrow, eyes, adrenals, thyroid, testis, epididymis, bladder, prostate, muscle, pancreas, salivary glands, lymph nodes, esophagus, stomach, large and small bowel, spleen.

1013

Animal #232 Pancreas - islet cell hyperplasia, focal. Pituitary - chromophobe, adenoma. Adrenals - focal cortical vacuolization. Severe tracheitis. Lungs - severe chronic broncheitis and severe acute and chronic pneumonia. Colon - parasite. Heart - slight inflammation. Kidneys - moderate inflammation. Spleen - slight hematopoiesis. Liver - few portal round cells. Normal - bonemarrow, eyes, skin, CNS, salivary glands, lymph nodes, thyroid, parathyroid, esophagus, stomach, small bowel, muscle, bladder, testis, epididymis, prostate.

Animal #235 Testes - slight tubular degeneration. Seminal vesicles = severe inflammation. Heart - slight inflammation. Breast - fibroadenoma. Kidneys - moderate nephritis. Lungs - severe bronchitis and moderate pneumonia. Liver - portal areas show some round cells and moderate ductular proliferation. Normal - bonemarrow, eyes, CNS, muscle, bladder, epididymis, pituitary, thyroid, adrenals, spleen, esophagus, stomach, large and small bowel, pancreas, salivary glands, lymph nodes.

Animal #238 Heart - slight inflammation. Severe tracheitis. Lungs - severe bronchitis and acute and chronic pneumonia. Pituitary - chromophobe adenoma. Adrenals - moderate cortical vacuolization. Thyroid - adenoma. Chronic prostatitis. Testes - focal tubular degeneration and calcification. Severe arteritis of abdominal arteries. Kidneys - severe inflammation; cortical epithelial hamartoma. Liver - congestion; moderate round cells in parenchyma. Normal - CNS, bonemarrow, eyes, muscle, skin, bladder, epididymis, pancreas, salivary glands, lymph nodes, esophagus, stomach, large and small bowel, spleen.

Animal #240 Thyroid - adenoma. Chronic tracheitis. Colon - parasite. Heart and Kidneys - slight inflammation. Lungs - severe bronchitis and chronic pneumonia. Liver - round cells in portal areas and ductular proliferation. Normal - bonemarrow, eyes, skin, pituitary, CNS, adrenals, parathyroid, spleen, esophagus, stomach, small intestine, lymph nodes, salivary glands, pancreas, muscle, bladder, testis, epididymis, prostate.

GROUP F

Experiment No. B5251 T-II (100 ppm) sacrificed females.

Animal #251 Pituitary - tiny adenoma. Tracheitis. Lungs - moderate bronchitis and pneumonia. Adrenals - cortical hemorrhages and cysts. Breast - fibroadenoma. Heart - slight inflammation. Kidney - moderate nephritis. Normal - eyes, bonemarrow, CNS, skin, pancreas, salivary glands, lymph nodes, thyroid, esophagus, stomach, large and small bowel, muscle, bladder, uterus, ovaries, spleen, liver.

Animal #253 Pituitary - chromophobe adenoma. Slight endometritis. Heart and Kidneys - slight inflammation. Severe tracheitis. Lungs - severe bronchitis and focal pneumonia. Liver - moderate no. portal round cells. Parathyroid - adenoma. Adrenals - cortical hemorrhages. Normal - bonemarrow, eyes, CNS, skin, esophagus, stomach, large and small bowel, pancreas, lymph nodes, salivary glands, muscle, bladder, ovaries, spleen, thyroid.

Animal #254

Tracheitis. Lungs - chronic bronchitis and pneumonia. Pituitary - chromophobe adenoma. Slight endometritis. Heart - focal inflammation. Liver - focal round cells in parenchyma. Normal - eyes, bonemarrow, CNS, pancreas, salivary glands, lymph nodes, skin, adrenals, thyroid, parathyroid, muscle, bladder, ovaries, kidney, spleen.

Animal #256

Pituitary - small adenoma. Inflammation of uterus and cervix. Ovaries - one simple cyst. Adrenals - cortical hemorrhages; one has cortical adenoma. Tracheitis. Lungs - chronic bronchitis and focal pneumonia. Heart and Kidney - slight inflammation. Liver - few round cells and moderate congestion. Normal - CNS, eyes, bonemarrow, muscle, bladder, skin, thyroid, pancreas, salivary glands, lymph nodes, esophagus, stomach, large and small intestine, spleen.

Animal #257

Pituitary - chromophobe adenoma. Adrenals - cortical hemorrhages and cysts. Colon - parasites. Endometritis. Heart - slight inflammation. Lungs - chronic bronchitis and focal pneumonia. Normal - skin, bonemarrow, CNS, eyes, thyroid, parathyroid, pancreas, salivary glands, lymph nodes, esophagus, stomach, small bowel, bladder, muscle, ovaries, spleen, kidney, liver.

Animal #261

Breast - fibroadenoma. Tracheitis. Lungs - chronic bronchitis and pneumonia. Slight endometritis. Pituitary - chromophobe adenoma. Adrenals - cortical hemorrhages. Heart and Kidney - slight inflammation. Liver - few round cells. Normal - bonemarrow, eyes, CNS, pancreas, salivary glands, lymph nodes, skin, esophagus, stomach, large and small bowel, muscle, bladder, ovaries, cervix, thyroid, parathyroid, spleen.

Animal #263

Pituitary - chromophobe adenoma. Thymoma. Adrenals - cortical vacuolization. Colon - parasites. Endometritis. Ovaries - simple cysts. Heart and Kidneys - moderate inflammation. Lungs - chronic bronchitis and pneumonia. Liver - moderate round cells in portal areas with ductular proliferation. Normal - skin, eyes, CNS, bonemarrow, thyroid, parathyroid, esophagus, stomach, small bowel, bladder, muscle, cervix, lymph nodes, salivary glands, pancreas, spleen.

Animal #266

Breast - fibroadenoma. Pituitary - chromophobe adenoma. Severe broncheitis. Lungs - severe bronchitis and focal pneumonia. Heart and Kidneys - moderate inflammation. Liver - portal areas show moderate round cells and ductular proliferation. Normal - bonemarrow, CNS, eyes, adrenals, thyroid, skin, muscle, bladder, uterus, ovaries, pancreas, salivary glands, lymph nodes, esophagus, stomach, large and small bowel, spleen.

Animal #269

Severe tracheitis. (No lung section) Adrenals - cortical hemorrhages. Pancreas - focal inflammation. Colon - parasites. Severe arteritis in pancreas. Endometritis. Ovarian abscess. Ulcer-? in Skin or Bladder, Pituitary - adenoma. Adenocarcinoma in uterus. Heart and Kidney - moderate inflammation. Liver - few round cells in parenchyma and triads. Normal - bonemarrow, skin, eyes, CNS, thyroid, lymph nodes, salivary glands, esophagus, stomach, small bowel, muscle, spleen.

101

Animal #270 Thyroid - solid adenoma. Tracheitis.
Lung - slight bronchitis and focal pneumonia. Uterus - suppurative
endometritis and inflamed polyp. Pancreas - islet cell adenoma.
Heart and Kidney - slight inflammation. Liver - one neoplastic
nodule. Normal - eyes, bonemarrow, CNS, pituitary, skin, adrenals,
parathyroid, muscle, bladder, ovaries, esophagus, stomach, large
and small bowel, lymph nodes, salivary glands, spleen.

Animal #271 One adrenal - cortical hemorrhage.
Tracheitis. Lungs - slight chronic inflammation. Endometritis.
Heart and Kidneys - slight inflammation. Liver - few portal round
cells. Normal - bonemarrow, eyes, skin, CNS, esophagus, stomach,
large and small bowel, pancreas, thyroid, pituitary, lymph nodes,
salivary glands, muscle, bladder, ovaries, spleen.

Animal #280 Pituitary - chromophobe adenoma.
Parathyroid - hyperplasia. Adrenals - cortical hemorrhages and cysts.
Tracheitis. Lungs - moderate inflammation. Breast - adenocarcinoma.
Endometritis. Heart and Kidney - slight inflammation. Spleen -
some hematopoiesis. Normal - eyes, bonemarrow, skin, CNS, thyroid,
muscle, cervix, bladder, ovaries, pancreas, esophagus, stomach, large
and small bowel, liver.

Animal #282 Adrenals - cortical cysts and
hemorrhages; vacuolization. Pituitary - chromophobe adenoma. Endome-
tritis. Adenocarcinoma in pancreas. Spleen - hematopoiesis. Heart
and Kidney - minimal inflammation. Lungs - severe bronchitis, pneumonia
and abscess. Liver - few portal round cells. Normal - bonemarrow,
eyes, skin, CNS, thyroid, parathyroid, esophagus, stomach, large and
small bowel, salivary glands, muscle, bladder, ovaries.

Animal #294 Pituitary - chromophobe adenoma.
Endometritis. Ovaries - cysts. Adrenals - cortical hemorrhages and
cysts. Tracheitis. Lungs - severe bronchitis, pneumonia, alveolar
macrophages. Lymph nodes - brown pigment. Heart - slight inflam-
mation. Kidney - cortical cyst. Liver - few portal round cells.
Normal - skin, bonemarrow, eyes, CNS, esophagus, large and small
bowel, muscle, bladder, cervix, thyroid, parathyroid, pancreas,
salivary glands, lymph nodes, spleen.

Animal #298 Tracheitis. Lung - severe
bronchitis. Adrenals - cortical hemorrhages and cysts. Pituitary-
chromophobe adenomas. Breast - fibroadenoma. Suppurative endome-
tritis. Pancreas - islet cell hyperplasia. Heart and Kidneys -
minimal inflammation. Liver - small lymphogenous cyst. Normal -
skin, eyes, bonemarrow, thyroid, parathyroid, CNS, muscle, bladder,
ovaries, esophagus, stomach, large and small bowel, salivary glands,
lymph nodes, spleen.

GROUP G

Experiment No. B5251. T-II (100 ppm). Males. Found dead or
moribund sacrifice.

Animal #203 Moribund sacrifice. Skin - dermatofibroma or sarcoma.

Animal #210 Found dead. Spleen - cellular, probably hematopoiesis.

- Animal #213 Found dead. Lung - severe bronchitis.
- Animal #219 Found dead. Pituitary - chromophobe adenoma.
- Animal #221 Found dead. Skin - ulcer and inflammation. Lung - severe pneumonia and edema.
- Animal #225 Found dead. Reticulum cell sarcoma in lungs, liver, lymph nodes. Spleen - hematopoiesis.
- Animal #231 Severe granulomatous inflammation of lungs, spleen, liver; cause undetermined (? fungi).
- Animal #236 Found dead. Severe chronic nephritis, bilateral.
- Animal #239 Found dead. Pituitary - chromophobe adenoma.
-

GROUP H

Experiment No. B5251. T-II (100 ppm) Found dead or moribund sacrifice. Females.

- Animal #252 Moribund sacrifice. Breast - adenocarcinoma.
- Animal #255 Found dead. Breast - adenocarcinoma. Spleen - marked hematopoiesis.
- Animal #258 Found dead. Breast - adenocarcinoma.
- Animal #259 Found dead. Skin - fibrosarcoma. Lung - severe pneumonia.
- Animal #264 Found dead. Breast - adenocarcinoma.
- Animal #265 Moribund sacrifice. Spleen - hematopoiesis. Breast - fibroadenoma.
- Animal #267 Moribund sacrifice. Pituitary - chromophobe adenoma. Breast - cystic disease. Adrenals - cortical hemorrhages and cysts.
- Animal #268 Found dead. Breast - adenocarcinoma.
- Animal #276 Moribund sacrifice. Breast - adenocarcinoma. Kidney - severe nephritis. Lungs - minimal inflammation.
- Animal #281 Found dead. Pituitary - chromophobe adenoma.
- Animal #283 Moribund sacrifice. Pituitary - chromophobe adenoma.
- Animal #285 Moribund sacrifice. Breast - fibroadenoma. Spleen - hematopoiesis.
- Animal #286 Found dead. Skin - fibrosarcoma. Breast - fibroadenoma. Lung - severe pneumonia
- Animal #288 Found dead. Pituitary - chromophobe adenoma.
- Animal #289 Moribund sacrifice. Breast - adenocarcinoma. Pituitary - chromophobe adenoma. Spleen - hematopoiesis.

Animal #290 Moribund sacrifice. Breast - adenocarcinoma.
Pituitary - chromophobe adenoma.

Animal #291 Found dead. Spleen - hematopoiesis. Pituitary -
chromophobe adenoma. Breast - fibroadenomas and cysts. Kidneys -
slight inflammation. Adrenals - cortical hemorrhages and cysts.

Animal #292 Found dead. Breast - adenocarcinoma.

Animal #295 Moribund sacrifice. Breast - fibroadenoma. Uterus -
suppurative endometritis and inflamed polyp. Ovaries - OK.

Animal #299 Found dead. Kidney - small focus of granulomatous
inflammation. Lung - severe pneumonia, abscess, edema. Liver -
few round cells in parenchyma and triads.

Animal #300 Found dead. Spleen - reticulum cell sarcoma. (I see
no sections of lung or liver with sarcoma infiltrates). One section
of liver - normal. Breast - fibroadenoma.